

# Giant Primary Pulmonary Fibrosarcoma

Ramakant Dixit<sup>1</sup>, Paras Nuwal<sup>2</sup>, Parul Dargar<sup>2\*</sup>, Sidharth Sharma<sup>1</sup> and U.K. Mathur<sup>3</sup>

Departments of Pulmonary Medicine<sup>1</sup>, Pathology<sup>2</sup>, and Radiotherapy<sup>3</sup>, J.L.N. Medical College, Ajmer and B.J. Medical College<sup>\*</sup>, Ahmedabad, India

---

## ABSTRACT

---

A rare case of primary fibrosarcoma in a 48-year-old male is described who presented with a huge pulmonary mass on the left side. The diagnosis was established on fine needle aspiration cytology (FNAC) and percutaneous transthoracic lung biopsy, supported by immuno-histochemistry. [Indian J Chest Dis Allied Sci 2010;52:111-114]

**Key words:** Fibrosarcoma, Lung biopsy.

---

## INTRODUCTION

---

The fibrosarcomas are extremely rare pulmonary neoplasms that account for about 12% of all pulmonary tumours.<sup>1</sup> The diagnosis of a primary pulmonary fibrosarcoma is made only by exclusion, after a thorough clinical examination and radiological investigations. The tumour needs to be differentiated from other spindle cell proliferations and sarcomatous neoplasms that share a similar morphological picture.<sup>2</sup> To date, about 54 cases of primary fibrosarcoma of the lung, both in adult and children have been documented in the literature.<sup>3-8</sup> This report describes a case of a primary pulmonary fibrosarcoma presenting as a huge pulmonary mass that was diagnosed on FNAC and core biopsy.

---

## CASE REPORT

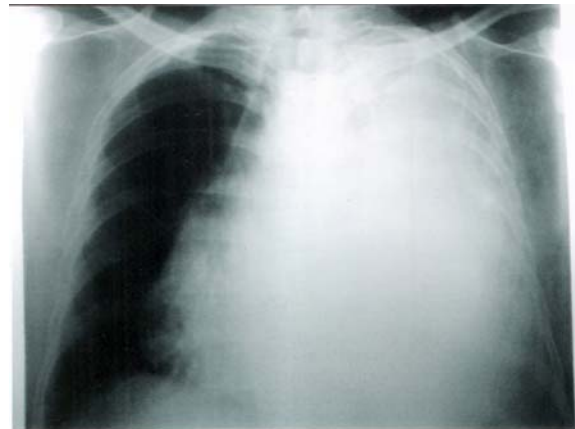
---

A 48-year-old male presented with a left-sided chest pain and dry cough for the last four months. He was a smoker and worked as an office clerk.

On general physical examination there was nothing abnormal. Respiratory system examination revealed a diffuse dull note, decreased breath sounds and vocal resonance over the left side with a shift of mediastinum towards the right side. Other systemic examination was unremarkable.

Investigations revealed a normal haemogram, blood biochemistry and a normal electrocardiogram (ECG). The chest radiograph showed a left opaque hemithorax with mediastinal shift to the right side (Figure 1). These findings were suggestive of a massive pleural

effusion on clinico-radiological assessment. However, thoracocentesis revealed a dry tap. Ultrasound of the chest disclosed a solid, smooth marginated mass occupying the left hemithorax with multiple well-defined rounded cystic spaces and focal areas of calcification. There was no pleural effusion. Ultrasound of the abdomen revealed no abnormality.



**Figure 1.** Chest radiograph showing left opaque hemithorax with mediastinal shift towards the right side.

Computed tomography (CT) of the thorax showed a well-defined heterogeneously enhancing mass measuring 16.6cm x 13.7cm, and occupying almost the whole of the left hemithorax. The mass showed non-enhancing areas with CT values of  $40 \pm 5$  HU suggesting a cystic degeneration and areas of calcification. The mass displaced the mediastinum to the right side with preservation of the fat planes between the mediastinum and the mass (Figure 2).

---

[Received: July 3, 2008; accepted after revision: April 15, 2009]

**Correspondence and reprint requests:** Dr Ramakant Dixit, Consultant Pulmonologist, 381/26, Ramganj, Ajmer - 305 001 (Rajasthan), India; Phone: 91-145-2691542; E-mail: ramakantdixit@gmail.com

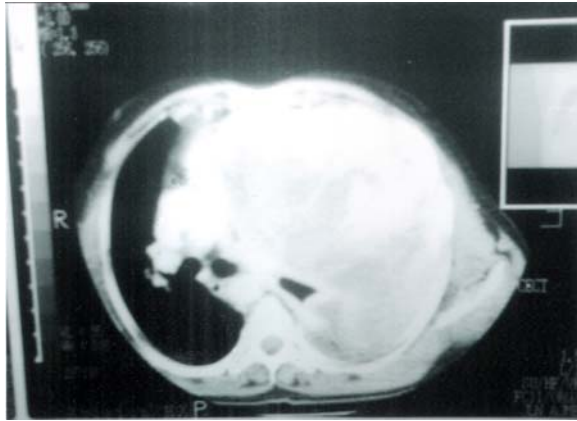


Figure 2. CT thorax showing a huge solid to cystic, well circumscribed mass with calcified areas, involving whole of the left thorax and mediastinum.

The right lung parenchyma appeared normal and there was no pleural effusion, pleural thickening or lymphadenopathy. Computed tomography of the abdomen was unremarkable.

Fine needle aspiration cytology of the mass was cellular with predominantly spindle cells arranged in small clusters that had large hyperchromatic nuclei and moderate eosinophilic cytoplasm against a haemorrhagic, necrotic and inflammatory background (Figure 3). A cutaneous transthoracic core biopsy revealed multiple greyish white tissues fragments.

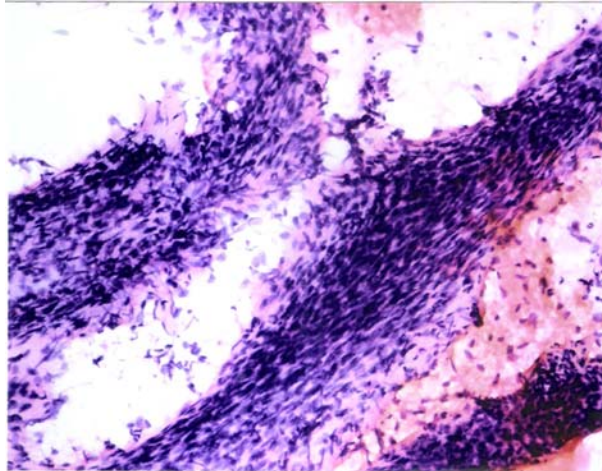


Figure 3. FNAC photomicrograph of lung mass showing clusters and sheets of spindle-shaped cells showing large hyperchromatic nuclei with abundant eosinophilic cytoplasm (Haematoxylin-Eosin x 400).

Histological examination of tissue sections revealed spindle cells arranged in interlacing bundles with broad fascicular or herring-bone pattern. There was pleomorphism and cytological evidence of malignancy (Figure 4). Up to 15 mitoses per 10 high-power fields were seen in most cellular areas. The features were suggestive of a fibrosarcoma lung. The biopsy tissues were also subjected to immunohistochemistry. The tumour cells were positive for vimentin (Figure 5) but non-

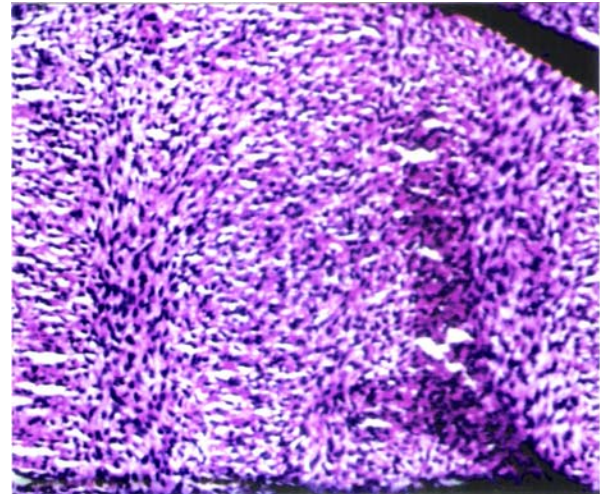


Figure 4. Photomicrograph of lung biopsy showing spindle-shaped cells arranged in interlacing bundles and showing pleomorphism with cytological evidence of malignancy (Haematoxylin-Eosin x 200).

reactive for cytokeratin, S100 protein, desmin,  $\alpha$ -smooth muscle actin and CD 34, further supporting the diagnosis of fibrosarcoma.

The patient received six cycles of chemotherapy with cyclophosphamide, adriamycin and vincristine. He developed chyleous ascites and died one year after the diagnosis.

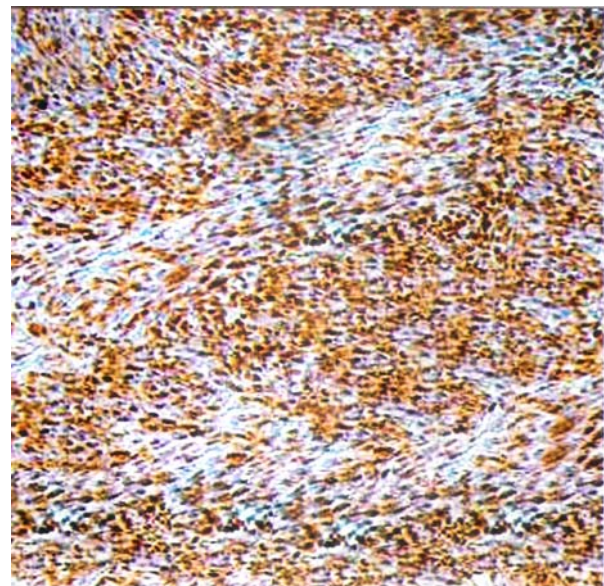


Figure 5. Photomicrograph of lung biopsy on immunohistochemical staining for vimentin showing diffuse positive reaction by tumour tissue (original magnification x 100).

## DISCUSSION

Fibrosarcoma of the lung is an extremely rare neoplasm that can arise from the trachea, bronchus,



pulmonary parenchyma or pulmonary artery. Most endobronchial tumours are seen in lobar or main bronchus of children and young adults while intrapulmonary tumours are seen usually in middle-aged and the elderly.<sup>9</sup>

Intrapulmonary fibrosarcomas often do not cause any symptoms, especially when small. Radiologically these present as a smooth or lobulated mass indistinguishable from other pulmonary masses. The endobronchial tumour often presents with cough, haemoptysis or chest pain, and radiologically may show atelectasis or obstructive pneumonia and rarely cavitation.<sup>9,10</sup> The presentation of the present case is unusual, as the patient had a huge pulmonary mass, almost completely occupying the left hemithorax, with a characteristic CT appearance of a giant cystic circumscribed solid mass with calcified areas. *To the best of our knowledge*, such a large, giant fibrosarcoma of the lung with no other lesion elsewhere in the body and characteristic CT appearance has not been described in the Indian literature previously.

The cytological features of fibrosarcoma lung includes oval-to spindle-shaped cells with slender nuclei, scanty cytoplasm, arranged singly or in fascicles with a prominent interweaving pattern<sup>3</sup>. Histologically the tumour is composed of fascicles of spindle-shaped neoplastic cells arranged in characteristic herring bone pattern with variable intercellular collagen.<sup>9</sup> The histological differential diagnosis of fibrosarcoma lung include other spindle cell neoplasms, such as leiomyosarcoma, monophasic synovial sarcoma, neurofibrosarcoma and intrapulmonary solitary fibrous tumour and sometime sarcomatoid mesothelioma.<sup>3</sup> However, tumours other than fibrosarcoma exhibit specific immunohistochemical staining, such as desmin,  $\alpha$ -smooth muscle actin, cytokeratin, epithelial membrane antigen, S100 protein, and CD 34.

Surgical resection remains the treatment modality of choice for primary pulmonary fibrosarcoma. The prognosis of these tumours is related to the tumour size, histologic grade, mitotic count and the location of the tumour (endobronchial *vs* intraparenchymal). Endobronchial tumours occur mostly in children and young adults, are usually detected earlier and have a better prognosis.<sup>6</sup> An intraparenchymal tumour often behaves in a highly malignant fashion with death occurring within 2.5 years. Tumours with  $\geq 8$  mitotic figures per 10 high-power fields behave in an aggressive fashion while others remains stationary or tend to grow slowly.<sup>9</sup>

Large/giant fibrosarcomas (>10cm size) seldom metastasise in contrast to a high incidence of metastasis of the small fibrosarcomas, although these have tendency for local extension into the adjacent pleura, chest wall and the mediastinum. By virtue of

their large size, death occurs within two years.<sup>6,9</sup> Guccion and Rosen<sup>6</sup> analysed 13 cases of pulmonary fibrosarcoma (3 endobronchial and 10 intrapulmonary). The largest tumour was 23cm in size and the patient died in four months in contrast to cases with small tumours of  $\leq 3.5$ cm size where the patients survived for more than two years. On the other hand, Fischer *et al*<sup>11</sup> reported a 61-year-old male with a 'giant fibrosarcoma' involving the lung and the chest wall where the patient underwent three extended resections including the chest wall followed by radiotherapy after last resection. This patient survived with no signs of recurrence after five years of the last resection, favouring multiple extended resections for large and aggressive sarcomas. However, other series report poor survival in general for tumours having a large size and grade three on TNM staging.<sup>12,13</sup>

There are only two reports in the Indian literature on primary pulmonary fibrosarcoma. Kamat *et al*<sup>5</sup> reported a 7cmx6cm size fibrosarcoma in the left lower lobe with an upper lobe invasion across the fissure. The patient was managed by pneumonectomy following which he survived for nine months and died with cerebral metastasis. Sinha *et al*<sup>14</sup> reported another case of pulmonary fibrosarcoma in the left lower lobe also involving the upper lobe and infiltrating into the pericardium and the diaphragm. This patient underwent pneumonectomy with removal of adjacent infiltrated structures. The left lung with tumour mass was five kilogram in weight. Following surgery, patient developed recurrent haemorrhagic pleural effusion that was managed by intrapleural and intravenous cyclophosphamide and later with local Co<sup>60</sup> exposure and intrapleural radioactive colloidal phosphorus with poor results and died on the 22<sup>nd</sup> post-operative day. However, unlike our case, both the above cases were diagnosed after pneumonectomy without immunohistochemistry and the patient survived less than one year even after major surgery.

---

## REFERENCES

---

1. Gebauer C. The postoperative prognosis of primary pulmonary sarcomas. *Scand J Thorac Cardiovasc Surg* 1982;16:91-7.
2. Suster S. Primary sarcomas of the lung. *Semin Diagn Pathol* 1995;12:140-57.
3. Logrono R, Filipowicz EA, Eyzaguirre EJ, Sawh RN. Diagnosis of primary fibrosarcoma of the lung by fine needle aspiration and core biopsy. *Arch Pathol Lab Med* 1999;123:731-5.
4. McLigeyo SO, Mbui J, Kungu A, Amayo E, Ogendo SWO. Fibrosarcoma of the lung with intrapulmonary manifestation: case report. *East Afr Med J* 1995;72:465-7.
5. Kamat MR, Mehta AR, Shrikhande SS. Fibrosarcoma of lung: a case report. *Indian J Cancer* 1973;10:382-4.
6. Guccion JG, Rosen SH. Bronchopulmonary

- leiomyosarcoma and fibrosarcoma: a study of 32 cases and review of the literature. *Cancer* 1972;30:836-47.
7. Pettinato G, Manivel JC, Saldana MJ, Peyser J, Dehner LP. Primary bronchopulmonary fibrosarcoma of childhood and adolescence: reassessment of a low grade malignancy: clinicopathologic study of five cases and review of the literature. *Human Pathol* 1989;20:463-71.
  8. Turner MA, Horne CHW. Primary fibrosarcoma of lung and diabetes mellitus. *Br J Surg* 1970;57:713-5.
  9. Fraser RS, Muller NL, Colman N, Pare PD. Neuroendocrine neoplasms. In: *Fraser and Pare's Diagnosis of Diseases of the Chest*; 4<sup>th</sup> edn. Philadelphia: W.B. Saunders & Co.;1999: pp 1229-50.
  10. Goldthorn JF, Duncan MH, Kosloke AM, Ball WS. Cavitating primary pulmonary fibrosarcoma in a child. *J Thorac Cardiovasc Surg* 1986;91:932-4.
  11. Fischer S, Perrot M de, Sekine Y, Keshavjee S. Long term survival after resection of a fibrosarcoma involving the lung and chest wall. *Eur J Cardiothorac Surg* 2001;20:421-3.
  12. Porte HL, Metois DG, Leroy X, Conti M, Gosselin B, Wurtz A. Surgical treatment of primary sarcoma of the lung. *Eur J Cardiothorac Surg* 2000;18:136-42.
  13. Nascimento AG, Unni KK, Bernatz PE. Sarcomas of the lung. *Mayo Clin Proc* 1982;57:355-9.
  14. Sinha K, Lal P, Agarwal PK, Charan A. Primary fibrosarcoma of the lung. *J Indian Med Assoc* 1974;63:189-90.