

# Morgagni Hernia with Down Syndrome: A Rare Association

M.H. Beg, M. Ehsan Rashidi and Vipin Jain

Department of Surgery, J.N.M.C.H., Aligarh Muslim University, Aligarh (Uttar Pradesh), India

---

## ABSTRACT

---

We report a case of a 22-year-old male with Down syndrome and Morgagni hernia, who presented to us with complaints of cough, regurgitation and vomiting. He was successfully treated surgically and the defect was repaired with prolene mesh. [Indian J Chest Dis Allied Sci 2010;52:115-117]

**Key words:** Morgagni hernia, Mesh repair, Down syndrome.

---

## INTRODUCTION

---

Morgagni hernias arise as an anterior diaphragmatic defect occurring on the right side and are located in the anterior mediastinum. Patients presenting in the pediatric age groups usually have features of respiratory distress while older patients present with features of gastrointestinal symptoms. Most cases of Morgagni hernia occur as isolated defect. However, Morgagni hernia detected during infancy is often associated with other congenital anomalies, such as congenital heart disease, Turner syndrome with coarctation, *Pectus Carniatum*, William syndrome, Prader-Willi syndrome, Cantrall syndrome, Noonan syndrome, Omphalocele, retroperitoneal teratoma, and genitourinary anomalies.<sup>1-9</sup> Only a few cases have been reported in association with Down syndrome.<sup>7,10</sup> We report a case of Down syndrome with Morgagni hernia in a 22-year-old male, because of the rare association of the two conditions.

---

## CASE REPORT

---

The patient was a mentally challenged, 22-year-old male, the last born child to a mother at the age of 36 years. The parents reported that the patient was floppy at birth and had delayed developmental milestones in comparison to his siblings. On examination, the patient had a mongoloid face, a flattened occiput, hypertelorism, wide saddle gap and short stature of 150cm. The karyotype of the patient further showed trisomy of chromosome 21. The patient presented to us with complaints of regurgitation of food, vomiting and cough on and off for the last three months.

Chest examination showed normal shape and symmetry. The movements were equal on both sides and the expansion was 5cm on maximum inspiration. On percussion, there was dullness in the lower part of the chest. On auscultation, there were decreased breath sounds on the lower chest and on the right side gurgling sounds were heard suggestive of bowel sounds. Rest of the systemic examination was normal.

Chest radiographs (postero-anterior view) showed bowel loops in anterior mediastinum (Figure 1), that was confirmed on barium meal (Figure 2) and computed tomography (CT). The patient was taken up for surgery. An exploratory laparotomy was done through an upper midline abdominal incision. A defect of around 10cm x10cm (Figure 3) was present

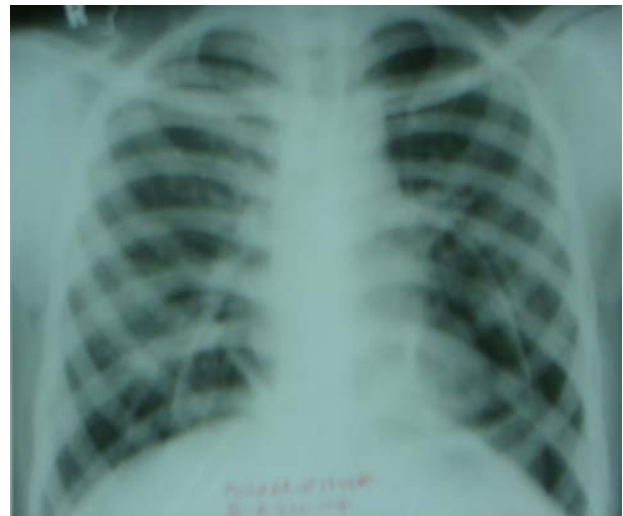

Figure 1. Chest radiograph (postero-anterior view) showing bowel loops in the lower chest.

---

[ Received: August 11, 2009; accepted: September 17, 2009]

**Correspondence and reprint requests:** Dr M.H. Beg, Professor, Division of Cardiothoracic and Vascular Surgery, Department of Surgery, J.N.M.C.H., Aligarh Muslim University, Aligarh-202 002(Uttar Pradesh), India; E-mail: mhbeg@rediffmail.com

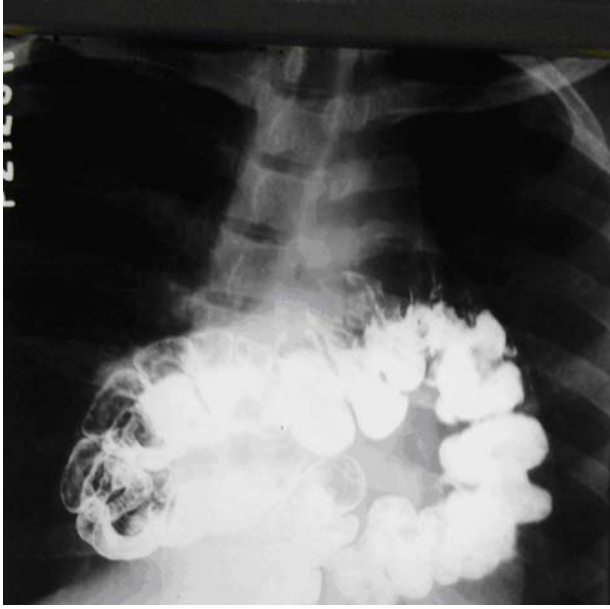


Figure 2. Barium meal follow through showing transverse colon in the lower chest.

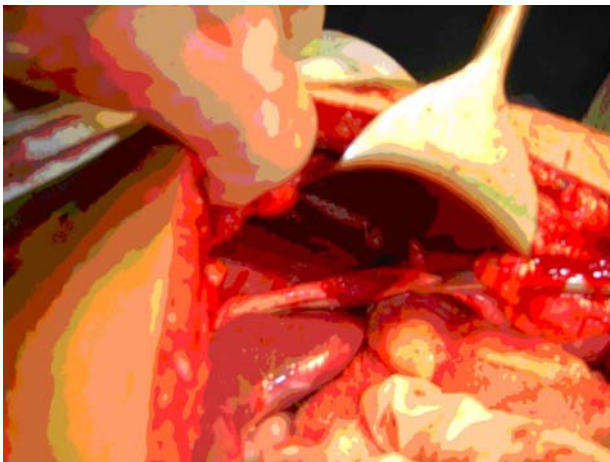


Figure 3. Diaphragmatic defects on surgical exploration.

in the anterior portion of the diaphragm. There was no hernial sac, and the right-side of diaphragm was thinned out. The transverse colon present in mediastinum was hypertrophied and adherent to pleura and pericardium. Adhesiolysis was done by a combination of blunt and sharp dissection. The transverse colon was repositioned in the abdominal cavity and the diaphragmatic defect was repaired with a double leaf prolene mesh (Figure 4).

A repeat barium meal follow through 10 days later revealed a normal study. The patient recovered uneventfully and there were no complaints on follow-up at two months.

---

## DISCUSSION

---

Embryologically, the foramen of Morgagni represents

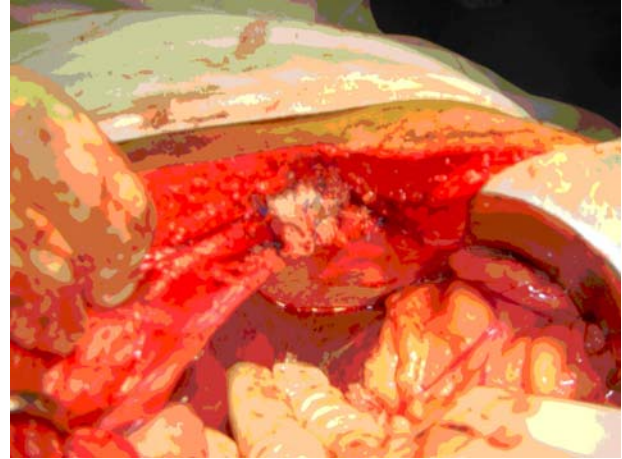


Figure 4. Defects repaired with prolene mesh.

the junction of the septum transversum, the anterior component of diaphragm, and the anterior thoracic wall. Morgagni hernia usually contains the transverse colon, omentum, liver and sometimes the small bowel or stomach. In our patient, the hernia contained transverse colon and its mesentery. The diagnosis of Morgagni hernia is based on lateral chest radiograph showing anterior herniation of bowel loops, which can be confirmed by barium meal follow through and CT. Complaints range from mild gastrointestinal symptoms to severe respiratory distress. Respiratory symptoms are more obvious in neonates while older patients are asymptomatic or have gastrointestinal symptoms. These hernias may be mis-diagnosed as localised diaphragmatic eventration, right middle lobe collapse, consolidation, pleuropericardial cyst or mediastinal lipoma and are often diagnosed incidentally on chest radiography as a homogeneous mass in the right cardiophrenic angle.<sup>11</sup>

Rarely, identical twin with Down syndrome having identical heart disease and Morgagni hernia have been reported.<sup>7</sup> This suggest a genetic component of Morgagni hernia. Morgagni hernia with Down syndrome has clinical implications too. In addition to screening for congenital anomalies in Down syndrome, a chest radiograph should be obtained for evidence of a Morgagni hernia. Early detection of Morgagni hernia has the potential benefit of early repair. This will prevent lung atelectasis and pneumonia<sup>7</sup> and emergency conditions, such as bowel ischemia and volvulus.<sup>5</sup>

The symptoms of Morgagni hernia are vague. Careful radiological examination, lateral chest radiograph, barium study and CT are helpful in establishing the diagnosis.<sup>3,5</sup> For repair we advocate a transabdominal route in the older patients. Better haemostasis, proper repositioning of bowel and convenience of operation are the advantages of this route. Newer approaches including video-assisted

thoracic surgery and laparoscopic repair hold promise for the future.

---

### REFERENCES

---

1. Pokorny WJ, McGill CW, Harberg FJ. Morgagni hernias during infancy: presentation and associated anomalies. *J Pediatr Surg* 1984;19:394-7.
2. Honore LH, Torfs CP, Curry CJ. Possible association between the hernia of Morgagni and trisomy 21. *Am J Med Genet* 1993;47:255-6.
3. Stolar CJH, Dillon PW. Congenital diaphragmatic hernia and eventration. In: O'Neill JA, Rowe MI, Grosfeld JL, Fonkalsrud EW, Coran AG, editors *Paediatric Surgery*; 5th edn. St. Louis: C.V. Mosby Co.; 1998:pp319-37.
4. Elawad ME. Diaphragmatic hernia in Down syndrome. *Ann Trop Paediatr* 1989;9:43-4.
5. Berman L, Stringer D, Ein SH, Shandling B. The late presenting paediatric Morgagni hernia: a benign condition. *J Pediatr Surg* 1989;24:970-2.
6. Groff DB. Diagnosis of a Morgagni hernia complicated by a previous normal chest x-ray. *J Paediatr Surg* 1990;25:556-7.
7. Harris GJ, Soper RT, Kimura KK. Foramen of Morgagni hernia in identical twins: is this an inheritable defect? *J Pediatr Surg* 1993;28:177-8.
8. Quah BS, Menon BS. Down Syndrome associated with retroperitoneal teratoma and Morgagni hernia. *Clin Genet* 1996;50:232-4.
9. Latif Al-Arfaj A. Morgagni hernia in infants and children. *Eur J Surg* 1998;164:275-9.
10. Comer TP, Clagett OT. Surgical treatment of hernia of the foramen of Morgagni. *J Thorac Cardiovasc Surg* 1966;52:461-8.
11. Eren S, Gumus H, Okur A. A rare cause of intestinal obstruction in the adult Morgagni's hernia. *Hernia* 2003;7:97-9.