

# Transthoracic Decompression of Emphysematous Bulla: A Novel Experience

P. Bhattacharyya<sup>1</sup>, S. Bardhan<sup>1</sup>, S. Nag<sup>1</sup>, S. Mukherjee<sup>2</sup> and A. Verma<sup>3</sup>

Institute of Pulmocare and Research<sup>1</sup>, and Departments of Cardiothoracic Surgery<sup>2</sup> and Anaesthesia<sup>3</sup>, Calcutta Medical College, Kolkata, India

---

## ABSTRACT

---

Emphysematous bullae are closed air containing spaces in lung parenchyma that may severely compromise lung function in patients of chronic obstructive pulmonary disease (COPD). We describe a simple and minimally invasive procedure to decompress a large emphysematous bullae in a patient with advanced COPD and high surgical risk. Transthoracic decompression of the bulla was accomplished under short-acting anaesthesia and muscle relaxation resulting in significant symptomatic, radiological and functional improvement. [Indian J Chest Dis Allied Sci 2011;53:51-53]

**Key words:** COPD, Emphysema, Chronic bronchitis, Transthoracic decompression.

---

## INTRODUCTION

---

Bullae are closed air containing spaces in the lung parenchyma.<sup>1,2</sup> At times, bullae may be large enough to produce symptoms and functional disability. Simultaneous compression atelectasis of surrounding normal parenchyma further jeopardises the lung function.<sup>3,4</sup> Hence, management of emphysematous bulla often becomes very important. Surgery happens to be the most commonly practiced definitive therapy for bullae.<sup>3</sup> However, it has significant intra- and post-operative morbidity and mortality due to generally poor lung functions.<sup>4</sup> Video assisted thoracoscopy has been used successfully for the resection of emphysematous bullae. However, intra-operative air leakage has proven to be a frequent problem with this procedure.<sup>5</sup> Intra-cavitary drainage has been attempted earlier. However, the procedure resulted in the development of prolonged air leaks, further necessitating fiberoptic intrabronchial intervention.<sup>6</sup> Options are limited for patients who refuse surgery or are unfit for it.

We report here a case of a patient having multiple emphysematous bullae with stage IV COPD who was treated with transthoracic decompression.

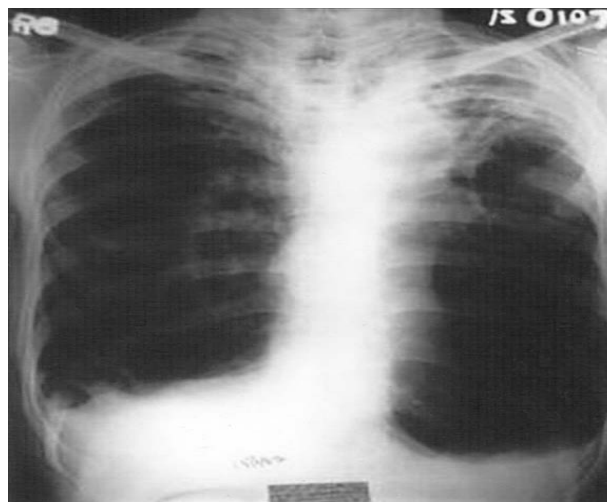
---

## CASE REPORT

---

A 58-year-old male, a known case of very severe COPD (stage IV) with multiple emphysematous bullae, was treated with a novel technique of transbronchial decompression of the largest bulla, five years back. The patient had significant improvement in symptoms and

lung function parameters following the procedure and was doing quite well. However in the last six months, he had recurrent episodes of acute exacerbations with a rapid down-hill course over the last four weeks. Clinical deterioration was to such an extent that the patient was totally confined within his premises and could barely manage to carry out his personal care. His lung function had deteriorated significantly (forced expiratory volume in one second [FEV<sub>1</sub>] less than 0.44L and the ratio of FEV<sub>1</sub> and forced vital capacity [FEV<sub>1</sub>/FVC] less than 0.33) with a resting oxygen saturation (SaO<sub>2</sub>) of around 90% breathing room air. Chest radiograph (Figure 1) and high resolution computed



**Figure 1.** Chest radiograph showing a large bulla in the left lower zone with concavity of the left dome of diaphragm.

[Received: November 13, 2009; accepted after revision: August 10, 2010]

**Correspondence and reprint requests:** Dr Parthasarathi Bhattacharyya, Consultant, Institute of Pulmocare and Research, CB - 16, Salt Lake, Sector I, Kolkata - 700 064 (West Bengal), India; Phone: 91-033-23580424; E-mail: parthachest@yahoo.com

tomography (HRCT) of thorax (Figure 2) showed a huge bulla in the left lower zone with inversion of the ipsilateral diaphragm. He was hospitalised on further deterioration of his clinical status. A repeat transbronchial decompression was attempted but failed. A transthoracic decompression was then planned since the surgical options were limited due to high risk.

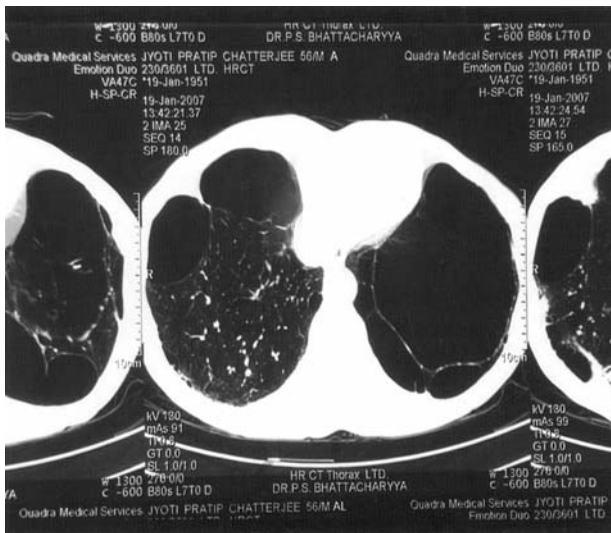

Figure 2. Pre-procedure HRCT showing a large bulla in the left lower lobe.

The proposed procedure was discussed with the patient and his relatives and the risks of thoracic surgery as an alternative mode of therapy were also explained. After an informed consent, we planned for a transthoracic decompression under short-acting anaesthesia with a cardio-thoracic surgery team on stand-by for emergency support.

In the operation theatre, the patient was oxygenated with low flow oxygen to maintain oxygen saturation levels around 98 percent to 100 percent. The prospective site for puncture was determined from the chest radiograph and HRCT views. Deep sedation was induced by propofol and a short-lasting muscle relaxation was attained with succinylcholine. Propofol being a sedative hypnotic with a rapid onset and termination of action, best suited our purpose. Thereafter, ventilation was maintained by an anaesthetic mask connected to Bain's Circuit with supplementation of 100% oxygen. Once deeply sedated and relaxed, a small (22 gauge) needle was used to puncture the bulla transthoracically at the selected site under aseptic measures. A guide wire was then passed through the needle and a paediatric subclavian catheter (Arrow International, Inc., 16Fr 0.9mm, 22G) was placed into the bulla following the dilatation of the passage using the Seldinger's technique. Thereafter, the air inside the bulla was

aspirated with the help of a 50cc syringe and the aspirated air was expelled to the atmosphere through an under-water drainage system with the help of a three-way stop cock fitted in between the catheter hub and the syringe (Figure 3).

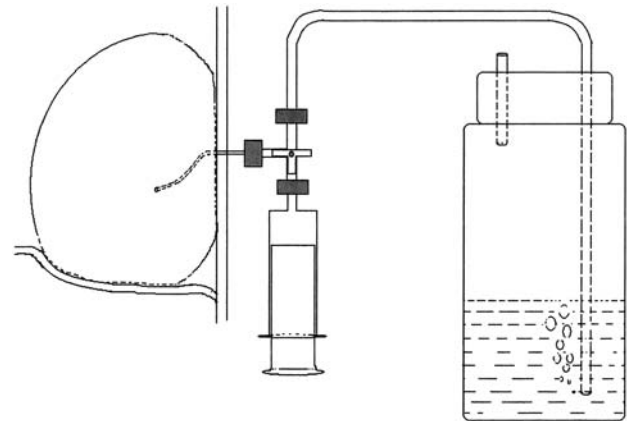


Figure 3. Diagrammatic representation of the procedure using a syringe, three-way cannula and water-seal drainage.

After aspirating about 800mL of air, the process was stopped and 10mL of freshly drawn (non-heparinised) blood from the patient's ante-cubital vein was quickly injected into the bulla before withdrawal of the catheter. The patient had a quick recovery from sedation and muscle relaxation. There was improvement of breath sound over the left infra-axillary and infra-mammary areas. Other than an occasional bout of cough on withdrawal of sedation, the entire procedure was uneventful. Immediately after the procedure, the patient had a pulse rate of 96 per minute, respiratory rate of 28 per minute, with an improved  $\text{SaO}_2$  of 98% on room air. He was able to go to the toilet within 30 minutes of the procedure without much distress.

A chest radiograph obtained half an hour after the procedure showed elevation of the left dome of diaphragm and a significant reduction in the size of the bulla. The spirometry performed next morning showed a significant improvement, with  $\text{FEV}_1$  increasing to 0.99L, and  $\text{FEV}_1/\text{FVC}$  to 0.43. The patient was discharged subsequently on the same day. A follow-up visit after 10 days revealed significant improvement in air entry, with a  $\text{SaO}_2$  of 96% to 97% on room air, a resting pulse rate of 80 per minute and a comfortable respiratory pattern. A repeat chest radiograph revealed the persistently decompressed state of the bulla obvious from its reduced diameter and correction of the diaphragm contour and position (Figure 4).

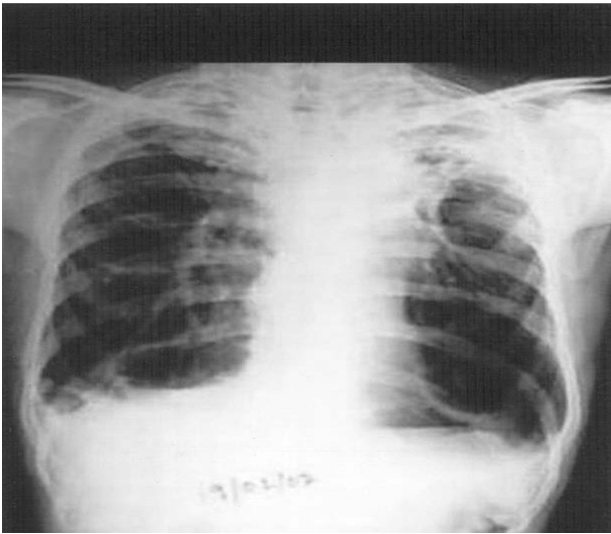


Figure 4. Chest radiograph done on the 10th post-procedure day showing reduction in size of the treated bulla.

## DISCUSSION

Our patient was an index case of a novel bronchoscopic decompression in the past.<sup>7</sup> However, the procedure failed this time due to inadvertent bleeding, probably from a vessel injury on attempting to penetrate the wall of the bulla with the transbronchial needle aspiration. This resulted in difficulty in visualisation along with worsening of hypoxaemia.

Transthoracic decompression of intra-pulmonary cavities had been attempted by Monaldi<sup>8</sup> for treatment of tuberculosis and the concept has already been applied to emphysematous bullae in the past.<sup>9</sup> We used short-acting anaesthesia (with propofol)<sup>10</sup> and muscle relaxation mainly to avoid the chance of pneumothorax resulting from any respiratory or unintentional voluntary movement during the process of insertion and withdrawal of the needle from the bulla. The pediatric subclavian catheter was chosen for its thin bore. Bullae have a tendency to enlarge progressively, trapping an increasingly larger volume of air over time.<sup>11</sup> Hence, autologous blood was instilled inside the bulla with an intention to induce an aseptic inflammation that might facilitate the closure of bronchial communications, if any. This may also result in thickening of the wall of the bulla so as to make it non-compliant for further expansion.<sup>12</sup> Significant decompression was achieved, reflected by the elevation and correction of contour and position

of the diaphragm. The bulla had become smaller and well defined. The functional improvement of the patient was remarkable and maintained on the follow-up visits.

A patient with a single big bulla is perhaps a more suitable candidate to be treated with transthoracic decompression than a patient with multiple emphysematous bullae. The advantage of this procedure is that it is practically bloodless and targets only a selected bulla thought to be causing the maximum functional disability. Although the long-term effect of instilling blood into the bulla is yet to be appreciated, the procedure is much less invasive than surgery and even thoracoscopy. Moreover, it is economical. In our opinion, this procedure deserves a trial with larger number of patients in future and may prove to be an alternate but easy and cost-effective method for the treatment of emphysematous bullae.

## REFERENCES

1. CIBA Foundation Guest Symposium. Terminology, definitions and classification of chronic pulmonary emphysema and related conditions. *Thorax* 1959;14: 286-99.
2. Uyama T, Monden Y, Harada K, Kimura S, Taniki T. Drainage of giant bulla with balloon catheter using chemical irritant and fibrin glue. *Chest* 1988;94:1289-90.
3. Kinnear WJ, Tattersfield AE. Emphysematous bulla. *Br Med J* 1990;300:208-9.
4. Shamii FM, Sachs HJ, Perkins DG. Cystic disease of lung. *Surg Clin North Am* 1988;68:581-620.
5. Mc Kenna RJ Jr, Brenner M, Gelb AF, Mullin M, Singh N, Peters H, et al. A randomised prospective trial of stapled lung reduction versus laser bullectomy for diffuse emphysema. *J Thorac Cardiovasc Surg* 1996;111:317-22.
6. Takizawa H, Kondo K, Sakiyama S, Monden Y. Computed tomography guided drainage for large pulmonary bulla. *Int Cardiovasc Thorac Surg* 2004;3:283-5.
7. Bhattacharyya P, Sarkar D, Nag S, Ghosh S, Roychowdhury S. Transbronchial decompression of emphysematous bulla: a new therapeutic approach. *Eur Respir J* 2007;29:1003-6.
8. Head JR, Avory EE. Intracavity suction (Monaldi) in the treatment of emphysematous bulla and blebs. *J Thoracic Surg* 1949;18:761-76.
9. Macarthur AM, Fountain SW. Intracavity suction and drainage in the treatment of emphysematous bullae. *Thorax* 1977;32:668-72.
10. Schnittger T. Intravenous propofol anesthesia. *West J Med* 1990;153:312.
11. Snider GL. Reduction pneumoplasty for giant bullous emphysema. *Chest* 1996;109:540-8.
12. Stone DJ, Schwartz A. A long term study of natural history and effects of therapy. *Am Rev Respir Dis* 1960; 94:493-507.

## ATTENTION SUBSCRIBERS

Due to substantial increase in the cost of printing, paper, postal charges and other overhead expenses, it has been felt necessary to revise the subscription rates w.e.f. January, 2011. New rates are given below:

### Subscription Rates

[w.e.f. 1st January, 2011]

	Individual		Institutes/Hospitals/Colleges, etc.	
	India (in ₹)	Overseas (Airmail) (in US \$)	India (in ₹)	Overseas (Airmail) (in US \$)
Single Issue	400.00	60.00	500.00	100.00
Per Volume (4 issues)	1300.00	200.00	1800.00	350.00

1. Overseas subscription rates include airmail postal charges.
2. Subscription Agencies are eligible for a 10% discount on annual rates for institutional subscription only. Agencies must provide complete address of the institution for which subscription is sent in their subscription order.
3. Payments should be made only by **Banker's Cheque/Demand Draft**; drawn in favour of **The Director, V.P. Chest Institute, Delhi**.
4. **Subscription rates are not subject to any Tax Deduction at Source.**
5. Journal copies are mailed by Book Post (UPC) at the subscriber's risk.
6. Subscribers are advised to get their copies by "**Registered Post**" by making an advance payment of ₹400/- per year in addition to Subscription rates, if subscription is made for one year (in case of a single copy, ₹100/- to be added).
7. The rates are subject to revision at any time by announcement in the Journal.
8. Subscription can be enrolled only on receipt of full payment in advance. Copies will not be sent if part payment is received.
9. Our responsibility ceases once we hand over the copies to the Post/Courier Office. We are not responsible for any delay/loss/damage in transit. We hold the receipt from the Post/Courier Office as proof. The Journal Office is not liable to replace copies lost in transit.
10. **Requests for missing issues will be considered if made within one month of the publication of a particular issue (i.e. for January-March issue → upto April, for April-June issue → upto July, for July-September issue → upto October and for October-December issue → upto January). Supply of replacement copy will be subject to availability.**

*Publishers/Editor-in-Chief*