

# Rare Presentation of Spontaneous Acquired Diaphragmatic Hernia

Shweta Gupta<sup>1</sup>, Roseleen Kaur Bali<sup>1</sup>, Kamanasish Das<sup>1</sup>, Anula Sisodia<sup>2</sup>, R.K. Dewan<sup>2</sup> and Rupak Singla<sup>1</sup>

Departments of Tuberculosis and Respiratory Diseases<sup>1</sup> and Thoracic Surgery<sup>2</sup>, L.R.S. Institute of Tuberculosis and Respiratory Diseases, New Delhi, India

---

## ABSTRACT

---

Spontaneous acquired diaphragmatic hernia without any apparent history of trauma is a very rare condition and is very difficult to diagnose. We present a case of a 21-year-old male who presented with abdominal pain for one month and four episodes of vomiting for one day. Clinical suspicion, chest radiography with nasogastric tube *in situ* and computed tomography (CT) confirmed the diagnosis. The diaphragmatic defect was repaired surgically. The patient had an uneventful post-operative recovery. [Indian J Chest Dis Allied Sci 2011;53:117-119]

**Key words:** Spontaneous diaphragmatic hernia, Weight lifting.

---

## INTRODUCTION

---

Acute diaphragmatic herniations following abdominal trauma are rare, despite high prevalence of trauma. Upto 5% of trauma patients may suffer a traumatic diaphragmatic injury.<sup>1,2</sup> A spontaneous acquired diaphragmatic hernia without any apparent history of trauma is an even more rare presentation and is very difficult to diagnose.<sup>3</sup> Only a few cases of rupture of diaphragm without any history of trauma have been recorded in the literature. Heavy weight lifting may cause a spontaneous acquired diaphragmatic hernia, but this is extremely rare. Early recognition of a spontaneous acquired diaphragmatic hernia is of utmost importance because delay in the diagnosis may result in an increased morbidity and mortality. Despite the development and availability of new modalities of investigation including multi-slice CT and magnetic resonance imaging (MRI), a diaphragmatic rupture may still be overlooked if not evaluated with a fair degree of clinical suspicion. We report here a case of spontaneous acquired diaphragmatic hernia due to its rarity and the difficulty it poses in making of the diagnosis.

---

## CASE REPORTS

---

A 21-year-old, non-diabetic, non-hypertensive male student presented with complaints of pain abdomen in the epigastric region off and on for the last one month.

Pain was dull in nature, moderate in intensity, non-radiating and was getting aggravated with intake of meals. He also had four episodes of vomiting for last one day that contained food particles and was associated with pain in the abdomen. Initially, he presented to casualty of a multi-speciality hospital where on emergency investigations, a left hydro-pneumothorax was detected on the chest radiograph. An intercostal chest drain was inserted on the left side and subsequently patient was referred to us for further management. There was no complaint of fever, cough, chest pain. There was no significant past history.

His pulse rate, blood pressure, respiratory rate and temperature were 108 per minute, 100/70 mmHg, 20 per minute and 98 °F, respectively. Respiratory system examination revealed a shift of mediastinum to the right side with dull percussion note and a succussion splash on the left side. On auscultation, breath sounds were diminished in intensity on the left upper chest and were absent in the lower chest. Other systemic examinations including per abdominal examination did not reveal any abnormality. Routine blood investigations showed mild leukocytosis with mildly deranged liver function test. Chest radiograph (Figure 1) showed an air fluid level on the left side with mediastinal shift to the right side with left intercostal drain *in situ*. Arterial blood gas examination showed mild hypoxaemia with partial pressure of arterial oxygen (PaO<sub>2</sub>) of 78 mmHg on room air.

---

[Received: April 19, 2010; accepted after revision: September 28, 2010]

**Correspondence and reprint requests:** Dr Rupak Singla, Head, Department of Tuberculosis and Respiratory Diseases, L.R.S. Institute of Tuberculosis and Respiratory Diseases, Sri Aurobindo Marg, New Delhi-110 030, India; Phone: 91-011-26854922/ Extn 115; Fax: 91-011-26517834; E-mail: drrupaksingla@yahoo.com

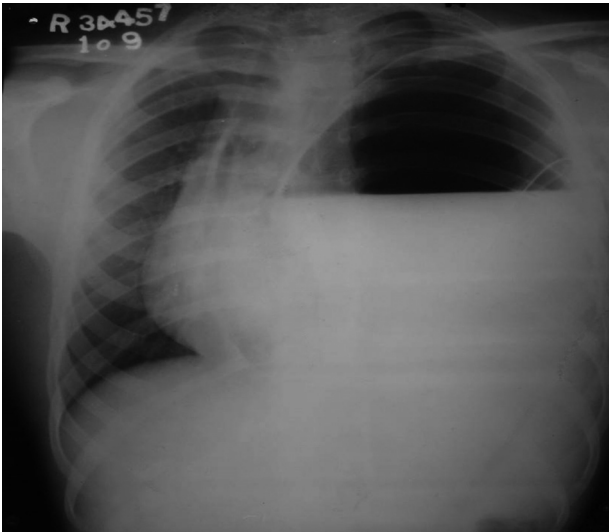


Figure 1. Chest radiograph (postero-anterior view) showing air fluid level on the left side with intercostal drain *in-situ*.

In view of abdominal complaints and absence of any pus or fluid in the intercostal drainage bag, a high index of suspicion was kept for diaphragmatic hernia. On further questioning, patient volunteered a history of heavy weight-lifting for muscle exercise followed by severe pain in the abdomen about a month back, subsequent to which all the current complaints started. A provisional diagnosis of spontaneous acquired diaphragmatic hernia following heavy weight-lifting was made.

A Ryle's tube was inserted and approximately 2.3 litre of brownish coloured fluid was aspirated. A repeat chest radiograph revealed decrease in air fluid level (Figure 2). Symptomatically, the patient had significant improvement. Computed tomography of chest was done that showed a defect on the left side of the diaphragm and herniation of stomach into the thoracic cavity (Figure 3).

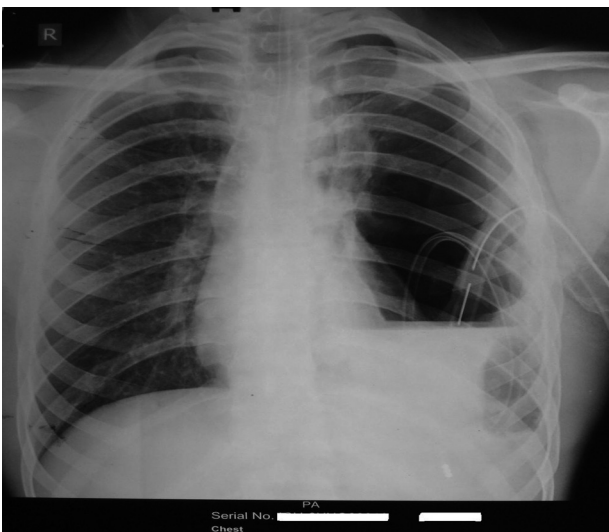


Figure 2. Chest radiograph (postero-anterior view) showing decrease air fluid level on the left side after inserting Ryle's tube.

Figure 3. CT of chest showing defect on left side of the diaphragm and herniation of stomach into the thoracic cavity.

The patient was then prepared for surgery. A left postero-lateral thoracotomy was carried out. The lung was found collapsed and contents of abdomen including more than half of stomach, spleen and greater omentum were found lying in the thoracic cavity. There was no damage to stomach wall despite the intercostal chest drain insertion. There was a rent in the anteromedial portion of the diaphragm that was closed by absorbable sutures and the repair was further reinforced with prolene mesh. Post-operatively, a chest radiograph (Figure 4) showed an expanded lung and the patient had an uneventful post-operative course.

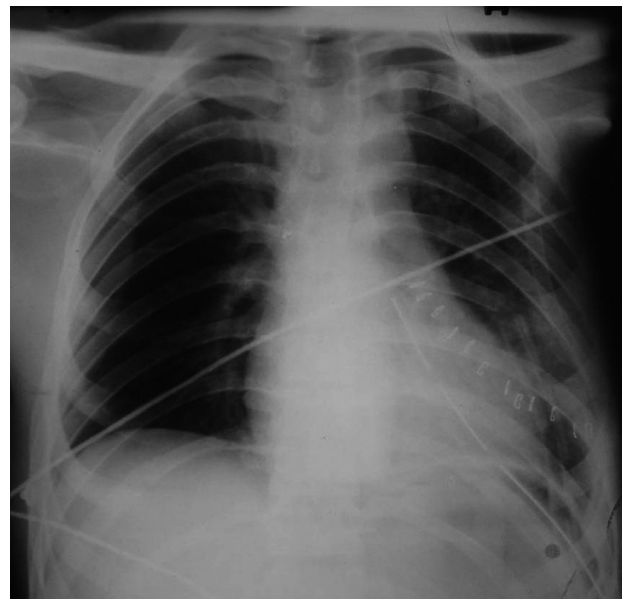


Figure 4. Post-operative chest radiograph showing the expanded lung.

---

## DISCUSSION

---

Acquired diaphragmatic hernias are usually traumatic and may be due to blunt or penetrating thoraco-abdominal trauma. Blunt thoraco-abdominal trauma accounts for 75% to 81% of all diaphragmatic trauma cases.<sup>4,5</sup> Road traffic accident is the most common cause.

Traumatic diaphragmatic injury may be suggested on chest radiographs but is more often diagnosed incidentally at surgery. The results of initial chest radiography are diagnostic or suggestive in only 28% to 64% of patients.<sup>6,7</sup> The most common side is left (57.0% to 87.5%) followed by right in 24% to 36% of patients.<sup>8</sup>

However, spontaneous acquired diaphragmatic hernias may also occur. They are most commonly found at the oesophageal hiatus or at the points of failure of embryonic fusion of diaphragm. The latter are usually subcostal (foramen of Morgagni, Larrey's spaces) or posterior (pleuroperitoneal or foramen of Bochdalek) in origin.<sup>9</sup> A 'spontaneous' rupture implies absence of trauma, but there is always the possibility that a diaphragmatic defect arose from some forgotten trauma in the past or has a structural origin.<sup>10</sup> The associated factors have included athletics, dancing, exercise,<sup>3</sup> eclampsia, weight-lifting,<sup>10</sup> labour,<sup>11,12</sup> violent emesis, asthma and pertussis. The liver,<sup>9,13,14</sup> stomach,<sup>11</sup> colon, spleen and small bowel<sup>10,15</sup> are the most commonly herniated organs.

Heavy weight-lifting can cause spontaneous acquired diaphragmatic hernia.<sup>10</sup> Spontaneous rupture is rare and may be difficult to diagnose.<sup>3</sup> In the present case, a sudden increase in intra-abdominal pressure while lifting weight was the likely cause.

Diagnosis is based on the 'clinical presentation', i.e. dyspnoea, palpitation, cyanosis, abdominal pain and abdominal distension, and confirmed by imaging, i.e. chest radiograph (nasogastric tube insertion), plain abdomen radiograph, abdominal CT, barium enema, upper gastrointestinal barium study and abdominal MRI. Chest radiograph has been found to be the best diagnostic aid and may show a unilateral elevation of diaphragm, sub-diaphragmatic densities and displacement of abdominal organs. Differential diagnosis includes, giant hiatal hernias, congenital diaphragmatic hernias, pulmonary sequestration, neoplasias, phrenic nerve palsy, atelectasis, sub-pulmonic effusion, sub-pulmonic abscess and eventration of the diaphragm.<sup>16</sup> In the present case, the chest radiograph showed an air fluid level that was decreased on inserting the Ryles tube. Computed tomography confirmed the suspected diagnosis of diaphragmatic hernia.

The management of diaphragmatic hernia is surgical and consists of reducing the viscera and sealing the diaphragmatic defect either by open thoracotomy or by minimal access surgery. In our case diaphragmatic defect was sealed by open thoracotomy.

Complications of diaphragmatic hernia include volvulus formation, incarceration, strangulation, haemorrhage and perforation of a hollow viscus.

Prognosis is good in adults (<3% mortality), but poor when complications appears such as organ ischaemic change and haemorrhage.

To conclude, heavy weight-lifting can cause a spontaneous acquired diaphragmatic hernia. This condition is very rare and very difficult to diagnose unless a very high index of suspicion is kept in mind. A good history taking can give a clue. Surgical repair is the definitive treatment.

---

## REFERENCES

---

1. Rodriguez-Morales G, Rodriguez A, Shatney CH. Acute rupture of the diaphragm in blunt trauma: analysis of 60 patients. *J Trauma* 1986;26:438-44.
2. Beal SL, McKennan M. Blunt diaphragmatic rupture: a morbid injury. *Arch Surg* 1988;123:828-32.
3. Bisgaard C, Rodenberg JC, Lundgaard J. Spontaneous rupture of the diaphragm. *Scand J Thorac Cardiovasc Surg* 1985;19:177-80.
4. Shah R, Sabanathan S, Mearns AJ, Choudhury AK. Traumatic rupture of diaphragm. *Ann Thorac Surg* 1995;60:1444-9.
5. Simpson J, Lobo DN, Shah AB, Rowlands BJ. Traumatic diaphragmatic rupture: associated injuries and outcome. *Ann R Coll Surg Engl* 2000;82:97-100.
6. Brown GL, Richardson JD. Traumatic diaphragmatic hernia: a continuing challenge. *Ann Thorac Surg* 1985;39:170-3.
7. Gelman R, Mirvis SE, Gens D. Diaphragmatic rupture due to blunt trauma: sensitivity of plain chest radiographs. *Am J Roentgenol* 1991;156:51-7.
8. Holm A, Bessey PQ, Aldrete JS. Diaphragmatic hernia due to blunt trauma: morbidity and mortality in 42 cases. *South Med J* 1988;81:956-62.
9. Poe RH, Schowengerdt CG. Two cases of atraumatic herniation of the liver. *Am Rev Respir Dis* 1972;105:959-63.
10. Jha P, Hutchinson S, Spychal B, Lee CY. Respiratory distress after heavy lifting. *J R Soc Med* 2004;97:290-1.
11. Dave KS, Bekassy SM, Wooler GH, Ionescu MI. Spontaneous rupture of the diaphragm during delivery. *Br J Surg* 2005;60:666-8.
12. Hamoudi D, Boudarka MA, Benissa N, Harti A. Diaphragmatic rupture during labor. *Int J Obstet Anesth* 2004;13:284-6.
13. Epstein RL, Hall RV, Gillespie JT, Hunt KK. Asymptomatic right lower thoracic nodule. *Chest* 1972;62:741-2.
14. Gupta S, Kulshreshtha R, Chhabra S. Non-traumatic herniation of the liver in an asthmatic patient. *J Postgrad Med* 2008;54:169-70.
15. Gupta V, Singhal R, Ansari MZ. Spontaneous rupture of the diaphragm. *Eur J Emerg Med* 2005;12:43-4.
16. Oh KS, Newman B, Bender TM, Bowen A. Radiologic evaluation of the diaphragm. *Radiol Clin North Am* 1988;26:355-64.