

Transbronchial Needle Aspiration with Rapid On-site Evaluation: A Prospective Study on Efficacy, Feasibility and Cost Effectiveness

Girish Sindhwani¹, Jagdish Rawat¹, Smita Chandra¹, Anuradha Kusum¹ and Manvinder Rawat¹

Departments of Pulmonary Medicine¹ and Pathology², Himalayan Institute of Medical Sciences, HIHT University, Dehradun (Uttarakhand), India

ABSTRACT

Background. Transbronchial needle aspiration (TBNA) has an established role in diagnosis of hilar and mediastinal lesions. Rapid on-site evaluation (ROSE) of TBNA smears can determine the adequacy of TBNA smears that can obviate the need for repeat procedures, thus avoiding added cost. There is paucity of data from India showing efficacy and cost-effectiveness of ROSE. Hence, this study was carried out to assess the efficacy, feasibility and cost implications of ROSE assisted TBNA.

Methods. Forty consecutive patients undergoing TBNA were enrolled and ROSE was performed on TBNA smears. The results were analysed using a comparative study design.

Results. It was found that 45% of patients would have required a repeat bronchoscopy due to inadequacy of material, if ROSE was not used. Inadequate smears were more common in benign aetiologies than malignant ones. TBNA of mass lesions and lesions with endoluminal bulge give better results than TBNA of lymph nodes and without endoluminal bulge.

Conclusions. ROSE was found to increase the yield of TBNA and help to prevent repeat procedures. It proved to be simple, cost-effective and feasible in Indian settings. [Indian J Chest Dis Allied Sci 2013;55:141-144]

Key words: Transbronchial needle aspiration, Rapid on-site evaluation, Bronchoscopy.

INTRODUCTION

Transbronchial needle aspiration (TBNA) is an established method of evaluation of paratracheal, parabranchial masses/lymph nodes with a yield ranging from 20% to 90%.¹⁻⁵ As the most common reason for a negative or non-diagnostic TBNA specimen is an inadequate sample, various methods like endobronchial ultrasound (EBUS), computerised tomography (CT) guidance and rapid on-site evaluation (ROSE) are being used to improve the yield. In developing countries like India, cost of EBUS remains prohibitive. Adequate localisation of the lesion on CT before TBNA is generally the only modality used to increase the yield. ROSE has been proved, in many studies⁶⁻⁸ worldwide, as an economical and effective way to improve the yield of TBNA. This involves an on-site evaluation of the TBNA smears by a cytopathologist in the bronchoscopy room. However, this modality is under-utilised in Indian subcontinent, as there is no data available from India on ROSE assisted TBNA. We are reporting our experience with 40 patients who underwent TBNA with ROSE in the present study.

MATERIAL AND METHODS

Efficacy, safety and feasibility of TBNA with ROSE were assessed in 40 consecutive patients undergoing TBNA from September 2011 to August 2012. Before bronchoscopy, all patients underwent contrast enhanced CT evaluation of the thorax. Patients with paratracheal, parabranchial lymph-nodes and mass lesions more than 1cm in cross-sectional diameter were selected for TBNA. Patients with severe respiratory, cardiac, other system comorbidity, coagulopathies and other contraindications for bronchoscopy, were excluded. Informed written consent for the procedure was obtained from all the patients.

For performing ROSE, a basic monocular microscope was permanently made available in the bronchoscopy suit. The cytopathologist was informed just before starting the procedure. TBNA was carried out under local anaesthesia and procedural sedation (Midazolam and Fentanyl) using a 21-gauge cytology needle (Olympus NA-2C-1). Smears were prepared and examined grossly. If the smears were considered 'visually adequate' (VA) by

[Received: October: 17, 2012; accepted after revision: April 18, 2013]

Correspondence and reprint requests: Dr Girish Sindhwani, Professor, Department of Pulmonary Medicine, Himalayan Institute of Medical Sciences, Swami Ram Nagar, Jolly Grant, Dehradun-248 140 (Uttarakhand), India; Phone: 91-135-2471362, 91-9411718286; Fax: 91-135-2471317; E-mail: girish_sindhwani@rediffmail.com, girish.sindhwani75@gmail.com

the bronchoscopist, no further TBNA passes were made. One of the smears was given to the cytopathologist for ROSE and the remaining smears were sent to the pathology laboratory for conventional staining, where these were air dried and stained with May-Grunwald Giemsa as well as alcohol-fixed and were stained by Haematoxyline and Eosin and Papanicolaou stains for definitive diagnosis. If the smears were considered visually inadequate (VI), TBNA was repeated until VA smears were obtained.

The stain used for ROSE was toluidine blue that was prepared by dissolving 0.5g of crystalline toluidine blue in 20mL of 95% ethanol and making the solution up to 100mL by adding distilled water, filtered and refrigerated till use. A drop of stain was put on the smear and covered with a cover slip. The slide was examined after a minute. The criteria used for adequate cellularity was the presence of 6-8 bronchial epithelial cells with atypical/malignant cells and/or the presence of reactive lymphoid population with lymphoglandular bodies. These were labelled as cellularly adequate (CA). Smears that showed only haemorrhage, necrosis, mucoid material or preponderance of bronchial epithelial cells, were considered as cellularly inadequate (CI).

In this way, two subgroups of the patients were formed: Group-I with VA=CA, i.e. patients who had TBNA smears that were both visually and cytologically adequate. This group of patients would not have required a repeat procedure if ROSE was not done. Group-II comprised of patients with VA=CI; these patients would have required a repeat bronchoscopy due to inadequate material (Figure). The two groups were compared for patient characteristics, site of TBNA, final diagnosis, bronchoscopy and radiology findings (Figure).

No further TBNA was attempted if the smears were categorised as CA, if the smears were found to be CI, TBNA was repeated until a CA was obtained. This step was not required for the study but to avoid a repeat bronchoscopy in patients with inadequate TBNA smears. In all these patients, TBNA was repeated to get a clinically adequate material, i.e. on 'intention to treat' basis.

During and until two hours after the bronchoscopy, the patients were monitored for signs/symptoms of possible complications, like bleeding, pneumothorax, pneumomediastinum, etc. A chest radiograph two hours after TBNA is a routine at our centre to rule out possible complications.

Statistical Analysis

Descriptive statistics were calculated using Statistical Package for the Social Sciences (Version 17.0). Tests of significance were not applied to the findings because of the small sample size.

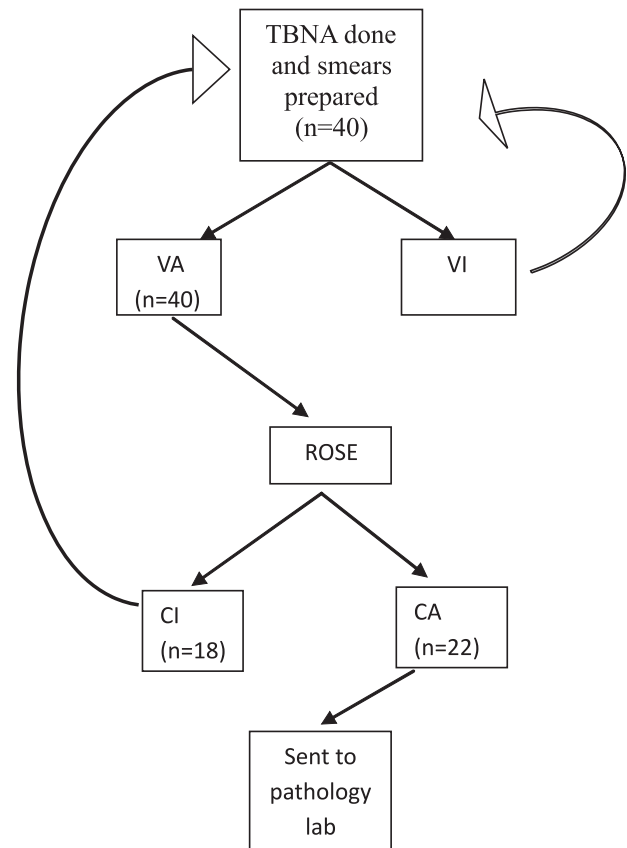


Figure. Procedure algorithm.

TBNA=Transbronchial needle aspiration, VA=Visually adequate, VI=Visually inadequate, ROSE=Rapid on-site evaluation, CI=Inadequate in cellularity, CA=Adequate in cellularity

Group-I: VA=CA at first ROSE of all VA (n=22)

Group-II: VA=CI at first ROSE of all VA (n=18)

RESULTS

A total of 40 consecutive patients were enrolled. Mean age (\pm standard deviation) of the patients was 55.1 ± 15.8 years. Thirty-two were males.

Overall yield of TBNA was 75% as 10 out of 40 patients remained undiagnosed by TBNA. In 22 out of 40 patients (55%), smears showed adequate cellularity on ROSE (Group-I VA=CA). The other 18 patients (45%) would have needed a repeat procedure if ROSE was not done (Group-II VA=CI). This implies that the minimum additional bronchoscopy cost will be 1.45 times per 100 patients. In addition, the cost of a basic monocular microscope is approximately INR 10000, which is a one-time cost and the cost of reagents used for ROSE is also nominal. This suggests that ROSE is cost-effective in Indian settings.

Sixteen of 24 (68.2%) patients proved to be malignant by TBNA would have required a repeat procedure if ROSE was not available. Four patients diagnosed to have sarcoidosis would have required a

repeat procedure if ROSE was not available. One patient of non-Hodgkin's lymphoma and tuberculosis (TB) each were found in both the groups (Table).

Bronchoscopy findings in both the groups of patients are given in the table. Endoluminal bulge was seen in 10 out of 22 patients in group-I and 5 out of 18 patients in group-II. This implies that if the paratracheal or parabronchial mass is causing compression, the chances of getting an adequate material increase (Table).

CT findings of both the groups suggest that TBNA of a mass lesion on CT could be a predictor of better outcome as compared to TBNA of lymph nodes (Table).

The site of TBNA is shown in the table. These findings suggest that TBNA of mass lesions results in a higher yield than sampling of lymph nodes. Also, chances of inadequate material in TBNA increased with station 4R (lower right paratracheal) TBNA than with station 7 (subcarinal).

In group-I, 23% of patients remained undiagnosed even though these smears were positive by ROSE. This suggests that ROSE can not be used as a substitute for conventional stains.

Table. Data comparing final diagnosis, bronchoscopic findings, radiological findings and site of TBNA of both the groups.

	Group-I (n=22)	Group-II (n=18)
Confirmed Diagnosis	17 (77%)	13 (72%)
NSCLC	10 (58.9%)	6 (46.2%)
SCLC	5 (29.4%)	1 (7.7%)
Sarcoidosis	0 (0%)	4 (30.8%)
Tuberculosis	1 (5.9%)	1 (7.7%)
NHL	1 (5.9%)	1 (7.7%)
Bronchoscopy Findings		
Endo-luminal bulge	10 (45.5%)	5 (27.8%)
Inflammation	2 (9%)	6 (33.3%)
Normal	10 (45.5%)	7 (38.9%)
CT Findings		
Isolated hilar (±) mediastinal LAP	6 (27.3%)	10 (55.6%)
Mass lesion with hilar/mediastinal LAP	3 (13.6%)	4 (22.2%)
Isolated mass lesion (Paratracheal/parabronchial)	13 (59.1%)	4 (22.2%)
Site of TBNA		
Mass lesion	14 (63.6%)	5 (27.8%)
Station 4R lymph node	5 (22.7%)	9 (50%)
Station 7 lymph node	3 (13.6%)	4 (22.2%)

NSCLC=Non-small cell lung cancer, SCLC=Small cell lung cancer, NHL=Non-Hodgkin's lymphoma, CT=Computed tomography, LAP=Lymphadenopathy, TBNA=Transbronchial needle aspiration.

No complications were observed in any patient immediately and up to two hours after the procedure, when the chest radiograph was done to rule out pneumothorax.

DISCUSSION

Transbronchial needle aspiration has a well established role in the evaluation of paratracheal, parabronchial masses/ lymph nodes with a yield ranging from 20% to 90%.¹⁻⁵ Despite a high yield of over 60% in most of the studies, reports of TBNA are few in India.^{9,10} From the literature, we could find only one Indian study¹¹ on TBNA, that was not assisted with ROSE. The present study is the first to report the experience of adding ROSE to TBNA.

We found an overall TBNA yield of 75% in our study that is comparable to previous studies.^{1-5,11} We also found that a minimum of 45% patients would have required a repeat procedure in the absence of ROSE, that would have added to the cost and inconvenience of a repeat bronchoscopy. Khan *et al*¹¹ also reported a diagnostic cytological yield of 40.4%. Other studies^{6,7} have also shown that ROSE decreases the number of specimen with inadequate material from 56% to 18%. A large randomised controlled trial⁸ involving 179 patients undergoing TBNA of hilar and mediastinal lymphadenopathy to assess the efficacy of ROSE showed that ROSE could prevent additional biopsies without the loss of diagnostic yield. A study by Daniel *et al*¹² also revealed that ROSE could prevent additional investigations, and hence, reduce the cost.

In ROSE, our cytopathologist used toluidene blue as the rapid stain. This stain is economical and requires only a minute of exposure to the material without any other processing. The stain has been shown to be effective for ROSE by other researchers as well.⁶ Besides toluidene blue, Diff quick rapid stain has also been used by cytopathologists for ROSE.⁸ However, there are no studies to compare the efficacy of different stains.

Eight of 24 patients (33%) with malignancy would have required a repeat procedure in the absence of ROSE while in all confirmed cases of sarcoidosis, ROSE could prevent a repeat procedure suggesting that chances of getting a cytologically adequate smear are less in patients with sarcoidosis. Since the number of patients confirmed for TB and NHL was very low in our series, it is not possible to comment on these cases with confidence. However, previous studies^{13,14} have shown significant TBNA diagnostic yield in patients with TB and sarcoidosis, and there are studies^{1,6} to show that the diagnostic TBNA yield for benign lesions is less than for the malignant ones.

Another observation in group-I was that 23% patients remained undiagnosed even though ROSE

showed adequate cellularity (false positivity on ROSE). This may be because of observer's error or limitation of the rapid stain to assess the cytological details in comparison to the conventional stains. Hence, ROSE can not be a substitute for conventional stains but is a rapid on-site tool to assess the adequacy of TBNA smears. Our results also give an impression that ROSE is more beneficial when there is no endobronchial bulge. This finding has previously been found in other studies also.^{15,16}

TBNA has been reported to cause complications, like fever, bacteraemia, pneumothorax, bleeding, pneumomediastinum and damage to the working channel of bronchoscope. However, these complications are very rare. None of the major studies have reported a significant complication rate with the procedure.¹ The study by Rocco *et al*¹³ has shown that ROSE assistance could actually prevent complications by avoiding additional biopsies that would have otherwise been needed to make a diagnosis. In our study as well no complications were observed in study patients and no damage to the bronchoscope occurred.

There were few limitations in our study. These include small sample size, lack of a randomised controlled study and small number of patients with benign aetiology. Nevertheless, the study has highlighted the fact that ROSE with TBNA improves diagnostic yield and reduces the need for repeat procedures, thereby reducing the cost. ROSE is simple, cost effective and is technically an easy procedure.

ACKNOWLEDGMENTS

The authors are thankful to the Department of Pathology for technical help.

REFERENCES

1. Amir S, Walid, Arnold BG, Linda G. Yield of transbronchial needle aspiration in diagnosis of mediastinal lesions. *Chest* 2003;124:2131-5.
2. Harrow EM, Abi-Saleh W, Blum J. The utility of transbronchial needle aspiration in the staging of bronchogenic carcinoma. *Am J Respir Crit Care Med* 2000;161:601-7.
3. Castela J, Buj J, Puzo C. Diagnosis and staging of bronchogenic carcinoma by transtracheal and transbronchial needle aspiration. *Ann Oncol* 1995;6 (Suppl.):S21-S24.
4. Gay PC, Brutinel WM. Transbronchial needle aspiration in the practice of bronchoscopy. *Mayo Clin Proc* 1989;64:157-62.
5. Schenk DA, Bowser JH, Bryan CL. Transbronchial needle aspiration staging of bronchogenic carcinoma. *Am Rev Respir Dis* 1986;134:146-8.
6. Davenport RD. Rapid on-site evaluation of transbronchial aspirates. *Chest* 1990;98:59-61.
7. Diacon AH, Schuurmans MM, Theron J, Louw M, Wright CA, Brundyn K, *et al*. Utility of rapid on-site evaluation of transbronchial needle aspirates. *Respiration* 2005;72: 182-8.
8. Rocco T, Alessandra C, Carmine T, Daniela P, Scudeller L, Casadei GP, *et al*. Rapid on-site evaluation of transbronchial aspirates in the diagnosis of hilar and mediastinal adenopathy: a randomized trial. *Chest* 2011;139:395-401.
9. Prakash UB, Offord KP, Stubbs SE. Bronchoscopy in North America: the ACCP survey. *Chest* 1991;100:1668-75.
10. Smyth CM, Stead RJ. Survey of flexible fiberoptic bronchoscopy in the United Kingdom. *Eur Respir J* 2002;9:458-63.
11. Khan A, Agarwal R, Aggarwal AN, Gupta N, Bal A, Singh N, *et al*. Blind transbronchial needle aspiration without an on-site cytopathologist: experience of 473 procedures. *Natl Med J India* 2011;24:136-9.
12. Daniel B, Ruel BG, Paul SR. Impact of rapid on-site cytologic evaluation during transbronchial needle aspiration. *Chest* 2005;128:869-75.
13. Rocco T, Carmine T, Alessandra C, Daniela P, Marco A, Maurizio B, *et al*. Transbronchial needle aspiration in sarcoidosis: yield and predictors of a positive aspirate. *J Thorac Cardiovasc Surg* 2008;135:837-42.
14. Semra B, zdenGu" nel, Nur E, Ufuk CM, Atul CM. Transbronchial needle aspiration in diagnosing intrathoracic tuberculous lymphadenitis. *Chest* 2004;126:259-67.
15. Diacon AH, Schuurmans MM, Theron J, Brundyn K, Louw M, Wright CA, *et al*. Transbronchial needle aspirates: how many passes per target site? *Eur Respir J* 2007;29:112-6.
16. Utz JP, Patel AM, Edell ES. The role of transcarinal needle aspiration in the staging of bronchogenic carcinoma. *Chest* 1993;104:1012-6.