

Recurrent Spontaneous Pneumothorax in Pregnancy

Vinay Kumar A. and Raghukanth A

Department of Pulmonology, Chalmeda Anand Rao Institute of Medical Sciences, Karimnagar (Andhra Pradesh), India

[Indian J Chest Dis Allied Sci 2014;56:33-35]

Clinical Summary

Spontaneous pneumothorax is rare in pregnancy and the common causes include rupture of subpleural apical bleb or bullae due to physiological changes of respiration during pregnancy and peri-partum periods.

Investigations

A 30-year-old female, gravid 2, para 2, live birth 1, abortion 0 (G2P2L1A0) at 36 weeks of gestational age presented with sudden onset of breathlessness, cough with expectoration since two days. There was no history of fever, chest pain, haemoptysis. She was a non-smoker. Her body mass index (BMI) was 21.2 Kg/m². There was no history of previous pulmonary disease. Antenatal ultrasonography was normal with adequate liquor. Routine antenatal investigations were normal except for the chest radiograph (postero-anterior view) which showed a right-sided pneumothorax (Figure 1). She was managed with intercostal tube (ICD tube) drainage underwater-seal and the pneumothorax resolved completely in a few

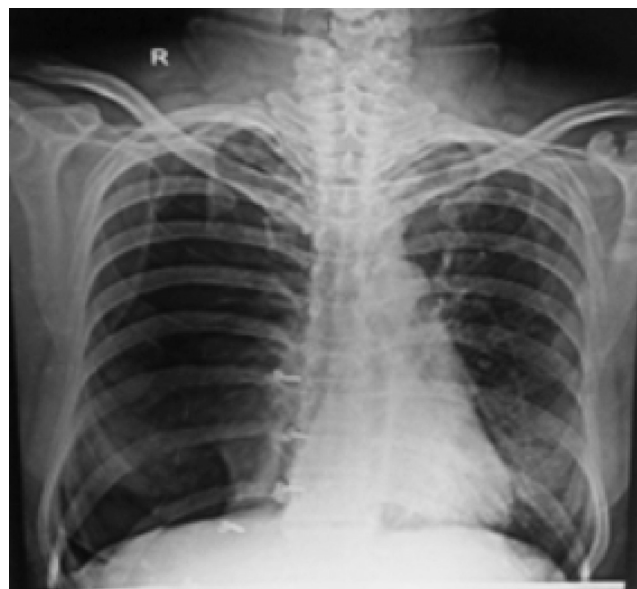

Figure 1. Chest radiograph (postero-anterior view) taken with abdominal shield obtained during the first episode showing right-sided pneumothorax.

days. At 40 weeks of gestational age she was re-admitted with similar symptoms. Repeat chest radiograph (postero-anterior view) showed recurrence of right-sided pneumothorax (Figure 2). She again underwent tube thoracostomy. After two days of treatment she complained sudden onset of left sided pleuritic chest pain. On examination, she was tachypnoeic; auscultation showed diminished breath sounds on the left side. Chest radiograph (postero-

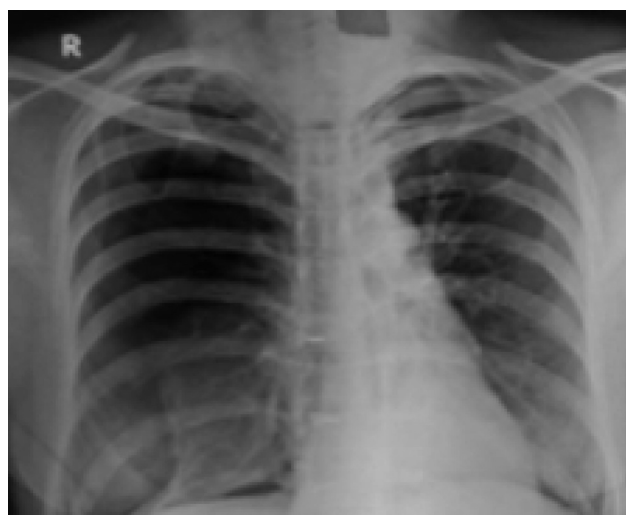

Figure 2. Chest radiograph (postero-anterior view) taken with abdominal shield obtained during the second episode showing right-sided pneumothorax.

anterior view) showed left-sided pneumothorax (Figure 3) and she was managed with tube thoracostomy.

Antenatal ultrasonography which revealed live foetus with severe oligohydramnios. Results of subsequent prenatal laboratory tests were normal. Healthy baby was delivered with an elective Caesarian section (CS) while the bilateral tube thoracostomies were *in situ*. Immediate post-operative period was uneventful. The case was further investigated after one week of post-CS with high resolution computed tomography (HRCT) of chest which showed bilateral upper lobe emphysematous changes (Figure 4); evidence of presence of intercostal tubes bilaterally and very minimal residual pneumothorax (Figure 5) and a small left-sided lingular area of consolidation.

[Received: January 28, 2013; accepted after revision: October 22, 2013]

Correspondence and reprint requests: Dr Vinay Kumar A., Associate Professor, Department of Pulmonology, Chalmeda Anand Rao Institute of Medical Sciences, Bommakal, Karimnagar-505 001 (Andhra Pradesh), India; Phone: 91-0878-6450797, 91-0878-2285565, Extn 310; E-mail: dr.vinay.mdc@gmail.com, raghukantharra@yahoo.com

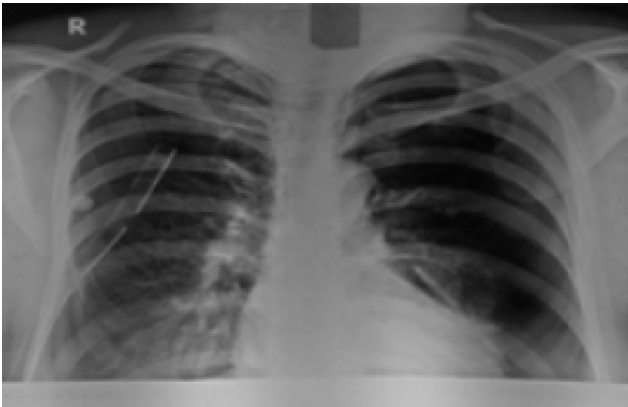


Figure 3. Chest radiograph (postero-anterior view) taken with abdominal shield during third episode showing left-sided pneumothorax. Intercostal tube is also evident on the right-side.

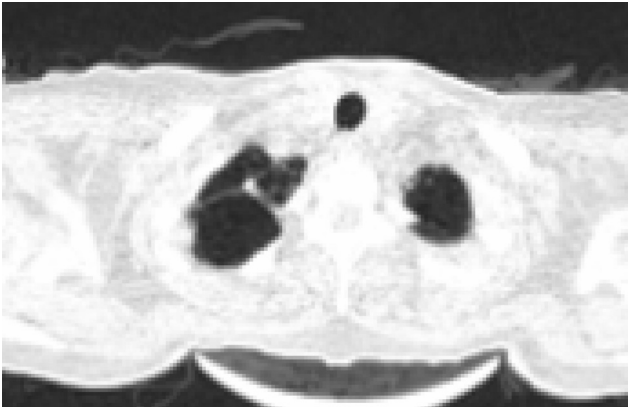

Figure 4. HRCT chest showing emphysematous changes in upper lobes.

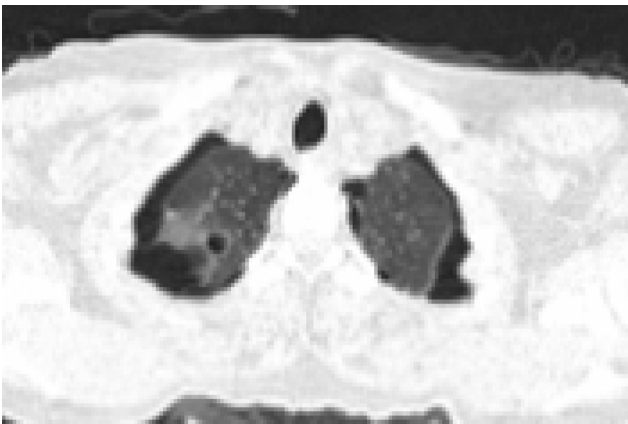

Figure 5. HRCT chest showing bilateral residual pneumothorax.

Later pleurodesis was done first on the right side and next on the left side through tube thoracostomy and intercostal tubes were removed on the next day. Even after pleurodesis, patient complained of right pleuritic chest pain. Repeat chest radiograph (postero-anterior view) showed right-sided partial pneumothorax with pleural thickening (Figure 6) and she was again managed with ICD tube insertion.

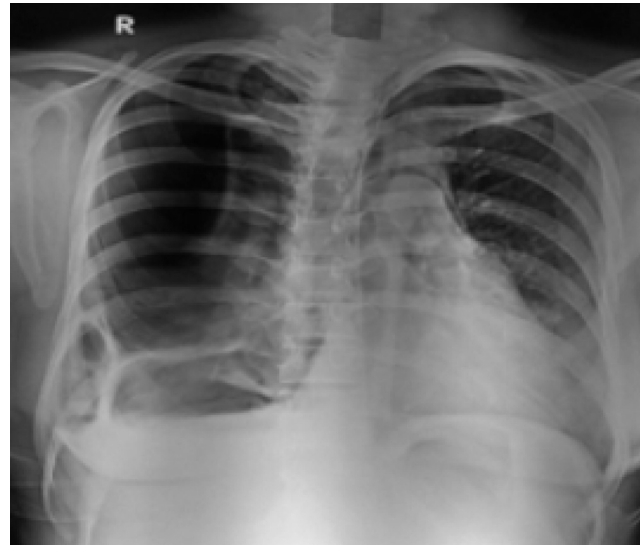


Figure 6. Chest radiograph (postero-anterior view) obtained during the fourth episode showing right-sided pneumothorax with right upper zone pleural thickening.

Diagnosis

Recurrent spontaneous pneumothorax in pregnancy.

Discussion

Spontaneous pneumothorax may occur as a primary event in pregnant women with normal underlying lungs (primary) or in women with chronic lung diseases (e.g., cystic fibrosis, emphysema, lymphangioleiomyomatosis, etc.).³ It is generally caused by the rupture of small apical blebs/bullae. Common risk factors include pulmonary infections, a past history of pneumothorax and asthma.¹ In pregnant women with sudden onset of respiratory distress, tension pneumothorax must be considered in the differential diagnosis.⁴ Risk of recurrence is 30%-40% particularly during labor.¹ The risk of recurrence following the initial episode is almost 30% and the risk thereafter is about 50% and overall incidence of recurrence is about 33%-44%.^{2,5}

Management of pneumothorax should follow standard protocol for drainage, which is indicated in large symptomatic primary pneumothorax, similar to that followed in a non-pregnant woman. Generally small bore needle tube is preferred over large bore tube as it is equally effective and is more tolerable for the patient.

In the presence of persistent air leaks/recurrent pneumothorax in pregnancy, video-assisted thoracoscopic surgery (VATS) with pleurectomy or pleural abrasion would be the ideal procedure to be undertaken. Chemical pleurodesis is an alternative procedure.⁶

In this scenario, vaginal delivery is the preferred mode of delivery. To prevent an increase in intrathoracic pressure during labor, epidural analgesics and instrumental delivery to cut-short second stage are recommended for those who have not undergone definitive surgical management.⁷

In the present case, as the patient's condition was further complicated by the presence of severe oligohydramnios, an elective CS was performed. As all investigations done to exclude causes of recurrent pneumothorax were normal the patient was diagnosed to have recurrent primary spontaneous pneumothorax was rendered. The present case also highlights the fact that while recurrent spontaneous pneumothorax is very rare in pregnancy standard treatment can result in a good perinatal outcome. Ideally procedure is VATS pleurectomy/pleural abrasion but chemical pleurodesis can be done as an alternative procedure particularly in developing countries.

References

1. Dhalla SS, Teskey JM. Surgical management of recurrent spontaneous pneumothorax during pregnancy. *Chest* 1985;86:301-2.
2. Fredman LJ. Antepartum spontaneous pneumothorax. *Diagn Gynecol Obstet* 1982;4:151-3.
3. Morgan RK, Ernst A. Interventional chest procedures in pregnancy. *Clin Chest Med* 2011;32:61-74.
4. Sills ES, Meinecke HM, Dixon GR, Johnson AM. Management approach for recurrent spontaneous pneumothorax in consecutive pregnancies based on clinical and radiographic findings. *J Cardiothoracic Surg* 2006;1:35.
5. Stewart B. Spontaneous pneumothorax and pregnancy. *Canadian Med Assoc J* 1979;121-5.
6. Wong MK, Leung WC, Wang JK, Lao TT, Ip MS, Lam WK, et al. Recurrent pneumothorax in pregnancy: what should we do after placing an intercostal drain? *Hong Kong Med J* 2006;12:375-80.
7. Van Winter JT, Nicholas FC, Pairolero PC, Ney JA, Ogburn PL Jr. Management of spontaneous pneumothorax during pregnancy: case report and review of the literature. *Mayo Clin Proc* 1996;71:249-52.

