

## Case Report

# Poncet's Arthritis in a Patient with Multidrug-Resistant Tuberculosis

Pavankumar R. Biraris, Vikram M. Rathi and Zarir F. Udwadia

Department of Pulmonary Medicine, P.D. Hinduja National Hospital and M.R.C., Mumbai, India

## Abstract

A 17-year-old female diagnosed to have multidrug-resistant pulmonary tuberculosis (MDR-TB), presented with Poncet's arthritis which responded to second-line anti-TB treatment. Poncet's disease is more commonly present in association with extra-pulmonary TB and involves large and small joints. However, our patient had pulmonary MDR-TB and small joint involvement. [Indian J Chest Dis Allied Sci 2015;57:195-198]

**Key words:** Poncet's arthritis, Multidrug-resistant tuberculosis, Small joint.

## Introduction

Poncet's disease is a rare syndrome described in 1897 by the Frenchman, A. Poncet<sup>1</sup>. It is characterised by articular impairment in patients diagnosed with tuberculosis (TB), not related to direct invasion by the micro-organism, but to an immune reaction to the TB protein, constituting a reactive arthritis. In contrast to the usual TB arthritis which is mono-articular infectious and destructive, Poncet's disease is a non-destructive para-infective polyarthritis occurring in patients with active TB, which resolves completely on anti-TB therapy. The literature related to this syndrome is scarce and restricted to case reports, which contributes to its under-diagnosis.

## Case Report

A 17-year-old female first developed pulmonary TB in 2009, but had defaulted first-line anti-TB treatment with daily isoniazid (H), rifampicin (R), ethambutol (E), and pyrazinamide (Z) three months after initiation. In February 2012 she presented to another hospital with symptoms of cough with expectoration, fever, weight loss of 3kg and anorexia. She was diagnosed to have

sputum smear-positive pulmonary TB and was re-started on a daily regimen consisting of first-line anti-TB drugs, namely, RHZE.

She presented to us in March 2013 with persistent symptoms of cough, fever, loss of appetite, weight loss of 5kg and joint pains mainly involving the small joints of both hands, despite being on afore-mentioned treatment for one year.

On physical examination patient had swelling of the inter-phalangeal joints of both hands with hyperflexion deformity at distal inter-phalangeal and hyperextension at proximal inter-phalangeal joints of index finger on both hands (Figure 1). Laboratory investigations including anti-cyclic citrullinated peptide (anti-CCP), rheumatoid factor and serum uric acid were normal; C-reactive protein (CRP) level was elevated (96mg/dL).

Chest radiograph (Figure 2) showed bilateral upper zone opacities with a cavity on the right side. Computed tomography (CT) of the thorax (Figure 3) showed bilateral consolidation with right upper lobe cavitation. Radiograph of both hands was normal (Figure 4) with no evidence of erosions, narrowing of joint space, peri-articular osteopaenia, subluxation or any gross deformity.




Figure 1. Photographs of the patient's hands before treatment [A- left hand and B- right hand] showing swelling of the inter-phalangeal joints with hyper-flexion deformity.

[Received: August 24, 2013; accepted after revision: December 8, 2014]

**Correspondence and reprint requests:** Dr Pavankumar R. Biraris, Department of Pulmonary Medicine, P.D. Hinduja National Hospital and M.R.C., Veer Sawarkar Marg, Mahim, Mumbai-400 016, India; E-mail: prbiraris@gmail.com

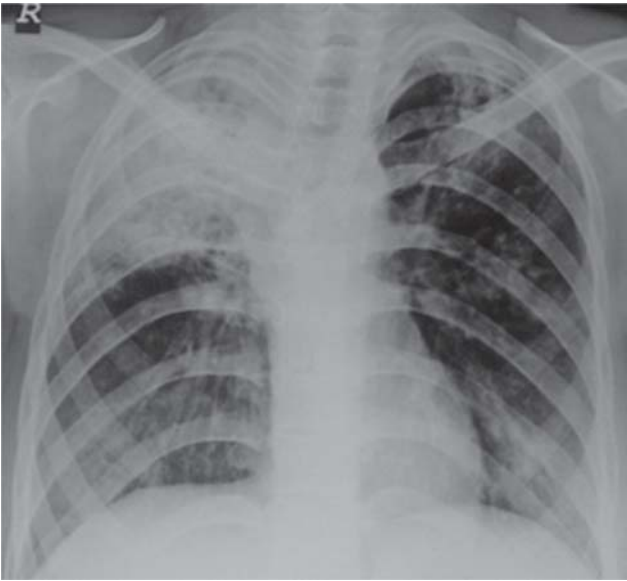

Figure 2. Chest radiograph (postero-anterior view) showing bilateral upper zone opacities with a cavity on the right side.

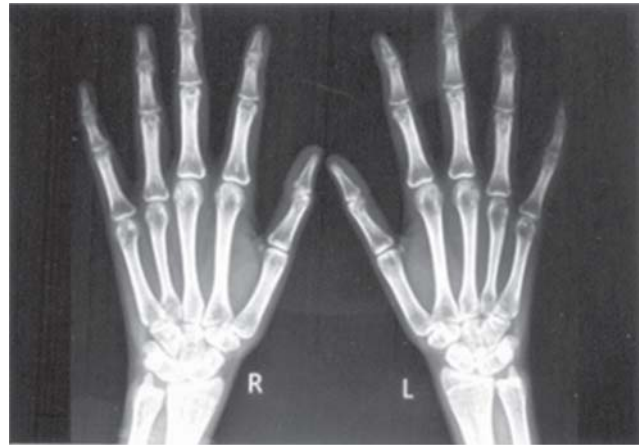

Figure 4. Radiograph of both hands.

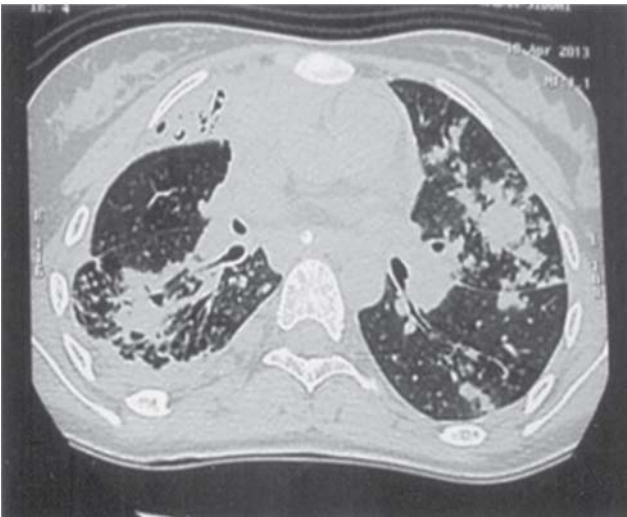

Figure 3. Computed tomography of thorax showing bilateral consolidation with cavitation of the right upper lobe.

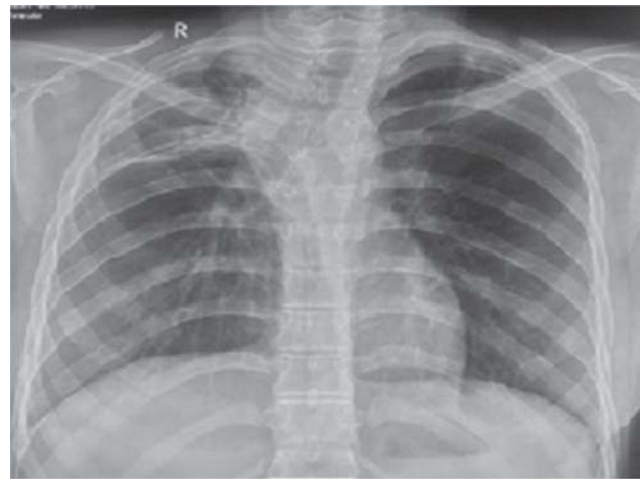


Figure 5. Chest radiograph after four months of MDR-TB treatment.

Sputum mycobacterial culture performed at Microbiology laboratory at the P.D. Hinduja National Hospital and M.R.C., Mumbai grew *Mycobacterium tuberculosis* which was resistant to H, R, streptomycin, kanamycin and amikacin suggestive of MDR-TB. On the basis of drug-susceptibility pattern; treatment was modified and she was treated with individualised

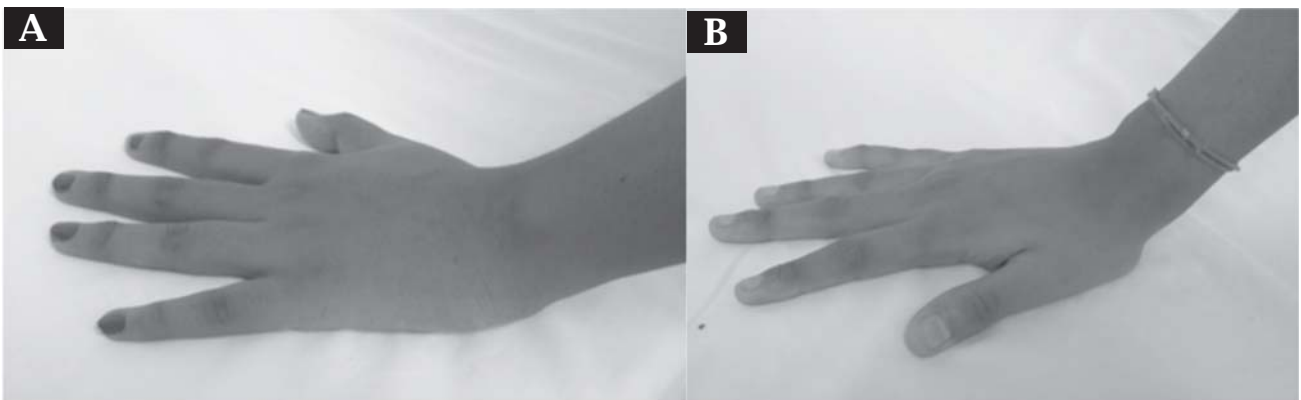


Figure 6. Photograph of both the hands (A-left hand, B-right hand) after four months of MDR-treatment showing complete resolution of swelling and deformity.

regimen containing Z, E, capreomycin, moxifloxacin, para-aminosalicylic acid and ethionamide. After four months of this treatment the patient improved radiologically (Figure 5), symptomatically and had gained 4kg weight. Repeat sputum mycobacterial culture was negative at four months of treatment. Joint pain and swelling subsided completely without leaving any residual deformity (Figure 6).

Patient was cured after completing 24 months of second-line anti-TB treatment.

## Discussion

In 1887 Poncet described an inflammatory arthritis in the joints of the hands and feet in 12 patients with past or present history of extra-pulmonary TB.<sup>1</sup> Poncet's disease has been defined as a "polyarthritis associated with visceral TB in which there is no evidence of bacteriologic involvement of the joints themselves."<sup>2</sup>

Tuberculosis can affect the joints in any of the following three ways: (i) direct musculo-skeletal involvement by the *Mycobacterium tuberculosis*, such as, spondylitis, osteomyelitis, septic arthritis, and tenosynovitis; (ii) anti-TB drug-induced rheumatologic syndromes, such as tendinopathies and drug-induced lupus; and (iii) reactive immune phenomena, such as reactive arthritis, erythema nodosum.

The TB septic mono-arthritis, in which the *Mycobacterium* can be isolated from the culture of the affected joint, is the more widely recognised form.<sup>3</sup> The involvement may be either by direct joint invasion of *Mycobacterium* or by immune reaction to TB protein.

Poncet's is mainly a disease of children or young adults with a slight female preponderance. These patients present with fever and constitutional symptoms associated with acute or sub-acute, symmetrical, peripheral inflammatory poly-arthritis predominantly involving the large joints. The knees are most commonly affected followed by ankles and then the wrists. Small joints may be affected in a symmetrical fashion resembling rheumatoid arthritis, but asymmetric involvement is also frequently seen. Although Poncet's is described as a polyarthritis, a review of the recent literature reveals Poncet's disease to be more often a pauci-articular, symmetrical, arthritis of predominantly the large joints. Joint effusions are very rare.<sup>2,4,5</sup> There is no microbiological evidence of mycobacterial invasion in the affected joint, the serological tests for autoimmunity are negative; the tuberculin test is positive, and acute phase proteins are elevated.<sup>6</sup> The most common extra-pulmonary focus of TB associated with Poncet's is lymph node.<sup>7,8</sup> Poncet's disease patients may go on to develop pleural or pulmonary TB during their course of illness.<sup>7,9,10</sup>

The following diagnostic criteria<sup>11</sup> have been proposed for the diagnosis of Poncet's arthritis: (i) evidence of active extra-articular TB; (ii) rheumatic manifestations in more than one joint; (iii) absence of

personal and family antecedents; (iv) lack of axial, vertebral column and sacroiliac impairment; (v) complete remission of the rheumatic manifestations with anti-TB treatment, and no permanent articular sequelae; and (vi) exclusion of other rheumatic diseases.

Our patient had small joint involvement of the hands, mainly inter-phalangeal joints with swelling, tenderness and flexion deformity at distal inter-phalangeal joints of the index fingers. Though many reports point towards the association of Poncet's with extra-pulmonary TB, it can be associated with active pulmonary TB as well.<sup>5,12</sup> In such cases the arthritis responds rapidly to the treatment than the pulmonary TB.<sup>13</sup>

Our patient had MDR-TB and bilateral involvement of more than one joint of the hands. There was no personal or family history suggestive of rheumatologic disease. There was no spine involvement. Anti-CCP and rheumatoid factor were negative, serum uric acid levels were normal and CRP levels were increased. With four months of second-line anti-TB treatment she had improved without any residual joint deformity. This rapid response is well documented, in patients with Poncet's arthritis compared to those with TB septic arthritis.<sup>3,6</sup> Many case reports document the disappearance of reactive arthritis soon after the initiation of anti-TB treatment,<sup>14</sup> but recurrent Poncet's arthritis has also been reported.<sup>15</sup>

In a review<sup>16</sup> of 198 cases with Poncet's arthritis, 35% of cases were from India. In a large series<sup>17</sup> from All India Institute of Medical Sciences, New Delhi (n=25), all the patients had mediastinal lymphadenopathy with bilateral ankle arthritis; histopathological confirmation of diagnosis of TB was established in nine patients. In another review,<sup>18</sup> of the 18 north Indian patients with ankle arthritis, eight had Poncet's disease which responded clinically and radiologically to anti-TB treatment.<sup>19-28</sup>

## References

1. Poncet A. "De la polyarthrite tuberculeuse deformante ou pseudo-rheumatisme chronique tuberculeux." *CongrFrChir* 2 (1897):2, 732. Cited from Gupta KB, Prakash P. Recurrent Poncet's disease: a rare presentation. *Indian J Tuberc* 2001;48:31-3.
2. Isaacs AJ, Sturrock RD. Poncet's disease: fact or fiction? A re-appraisal of tuberculous rheumatism. *Tubercle* 1974; 55:135-42.
3. Kroot EJ, Hazes JM, Colin EM, Dolhain RJ. Poncet's disease: reactive arthritis accompanying tuberculosis: two case reports and a review of the literature. *Rheumatology* (Oxford) 2007;46:484-9.
4. Bloxham CA, Addy DP. Poncet's disease: para-infective tuberculous polyarthropathy. *Br Med J* 1978;1:1590.
5. Arora VK, Verma V. Tuberculous rheumatism (Poncet's disease): three case reports. *Indian J Tuberc* 1991;38:229-230.
6. Malaviya AN, Kotwal PP. Arthritis associated with tuberculosis. *Best Pract Res Clin Rheumatol* 2003;17:319-43.
7. Bhargava AD, Malaviya AN, Kumar A. Tuberculous rheumatism [Poncet's disease]: a case series. *Indian J Tuberc* 1998;45:215-9.
8. Bahadur P, Seetharaman ML, Krishnamurthy H. Poncet's disease: report of a case. *Indian J Tuberc* 1988;35:28-9.

9. Kawasar M, D'Cruz D, Nathan M, Murphy M. Poncet's disease in a patient with AIDS. *Rheumatology [Oxford]* 2001;40:346-7.
10. Sood R, Wali JP, Handa R. Poncet's disease in a north Indian hospital. *Trop Doct* 1999;29:33-6.
11. Novaes GS, Kalil G, Borrelli FE. *Critérios de diagnóstico da doença de Poncet*. *Rev Bras Reumatol* 1992;32:20-6.
12. Singhanía P, Banerjee A, Singhanía B, Banerjee I, Kumar V, Maitra S. Poncet's disease or tuberculous rheumatism. *Ceylon Med J* 2011;56:43-4.
13. Han N, Lee SK, Kim TJ, Song YS, Jung SH, Yang KH, et al. A case of Poncet's disease in a patient with pulmonary tuberculosis accompanying erythema nodosum. *Tuberc Respir Dis* 2011;71:221-4.
14. Abdulaziz S, Almoallim H, Ibrahim A, Samannodi M, Shabrawish M, Meeralam Y, et al. Poncet's disease (reactive arthritis associated with tuberculosis): retrospective case series and review of literature. *Clin Rheumatol* 2012;31:1521-8.
15. Gupta KB, Prakash P. Recurrent Poncet's disease: a rare presentation. *Indian J Tuberc* 2001;48:31-3.
16. Rueda JC, Crepy MF, Mantilla RD. Clinical features of Poncet's disease from the description of 198 cases found in the literature. *Clin Rheumatol* 2013;32:929-35.
17. Duggal L, Khosla P. Bilateral ankle arthritis with mediastinal lymphadenopathy: a clinician's perspective. *APLAR J Rheumatol* 2006;9:264-8.
18. Garg S, Malaviya AN, Kapoor S, Rawat R, Agarwal D, Sharma A. Acute inflammatory ankle arthritis in northern India: Löfgren's syndrome or Poncet's disease? *J Assoc Physicians India* 2011;59:87-90.
19. Rajpal S, Dhingra VK, Chopra KK. Poncet's disease: a unique presentation. *Indian J Tuberc* 1999;46:133-5.
20. Rao H, Sharma LR, Rao N. Tuberculous rheumatism (Poncet's disease): a case report. *Indian J Orthop* 2002;36:53-4.
21. Shrivastav A, Mitra B, Pal J. Images in clinical tropical medicine: reactive arthritis (Poncet's disease) and erythema nodosum accompanying tuberculosis. *Am J Trop Med Hyg* 2009;80:501-2.
22. Ghosh GC, Sundriyal D, Chawla MPS, Gupta BB. A case of Poncet's disease. *J Indian Acad Clin Med* 2011;13:79-80.
23. Malik SK, Khatri GK, Deodhar SD. Tuberculous rheumatism (Poncet's disease). *J Indian Med Assoc* 1977;69:201-2.
24. Pande D, Dubey AP, Choudhury P. Poncet's disease. *Indian Pediatr* 1989;26:828-30.
25. Bhalerao S, Gautam D, Balani S, Kelkar PN, Apte NV, Rammoorthy K. Poncet's disease. *J Assoc Physicians India* 1992;40:467-8.
26. Kumar PD, Sasidharan PK, Paul BJ, Tharian G, Bhargavan PV. Poncet's disease. *J Assoc Physicians India* 1993;41:400.
27. Chaudhuri MK, Singh S, Kumar L. Poncet's disease: tuberculous rheumatism. *Indian J Pediatr* 1995;62:363-5.
28. Thakur S, Prasher BS, Sharma V. Poncet's disease: case report. *Indian J Med Sci* 1996;50:244-6.