

## Case Report

# Burkitt's Lymphoma: Thorax to Pelvis

S.K. Verma<sup>1</sup>, Neha<sup>1</sup> and Madhu<sup>2</sup>

Departments of Pulmonary Medicine<sup>1</sup> and Pathology<sup>2</sup>, King George's Medical University, Lucknow (Uttar Pradesh), India

## Abstract

Burkitt's lymphoma is a sub-group of non-Hodgkin's lymphoma of high-grade with an aggressive clinical course and is composed of diffuse, small and non-cleaved, undifferentiated malignant cells of lymphoid origin. Dennis Burkitt first described this entity in 1956 in equatorial Africa. It is one of the fastest growing cancers in humans with a growth fraction close to 100%. It commonly occurs in children and young adults, with frequent involvement of bone marrow and central nervous system. These are considered to be medical emergencies and require immediate diagnostic and therapeutic intervention. In this report, we present a case of Burkitt's lymphoma with unusual presentation with the involvement of both thorax and the whole of the abdomen. [Indian J Chest Dis Allied Sci 2016;58:49-51]

**Key words.** Burkitt's lymphoma, Thorax, Pelvis, Children.

## Introduction

Burkitt's lymphoma accounts for 0.8% of solid malignant tumours in children, and is thus, a very rare malignancy. Most of the cases reported in the literature have presented either as jaw tumours or an intra-abdominal malignancy. *To the best of our knowledge*, there is no report of Burkitt's lymphoma present as a huge mass extending from the thorax into the abdomen and pelvis in continuity. The case is being reported because of its rare presentation.

## Case Report

A 16-year-old, non-smoker male, presented with chief complaints of fever for three months, associated with progressive breathlessness and left-sided chest pain for two months. Fever was low grade, continuous and relieved on taking medications. Breathlessness was insidious in onset and gradually progressive to modified Medical Research Council grade IV and increased on lying in the right lateral position. Chest pain was insidious in onset, gradually progressive, localised to the left side of the hemithorax, non-radiating and without diurnal or postural variation. The patient also complained of abdominal distention for the past one month that was progressive and associated with dull aching pain. There was no history of cough, haemoptysis, pedal oedema, altered bowel habits, recurrent vomiting or reflux.

On initial examination, the patient was observed to have a respiratory rate of 30 per minute and an oxygen saturation of 92%. His blood pressure was 112/80 mmHg and the pulse rate was 110 per minute. On general examination, pallor was present. Left axillary (4cmx3cm,

single, mobile, firm) and left supraclavicular (2cmx1cm, single, mobile and firm) lymph nodes were palpable. On respiratory system examination, the chest was asymmetrical with reduced movement and fullness in the left hemithorax with dilated veins present on the left side of the chest. The trachea was shifted to the right. On percussion, a dull note was present all over the left hemithorax. On auscultation, breath sounds were diminished in the left hemithorax with decreased vocal resonance. Abdominal examination revealed a tense and tender abdomen. A plain chest radiograph (postero-anterior view) revealed a left-sided homogeneous opacity with a shift of the trachea and mediastinum towards the right side (Figure 1).

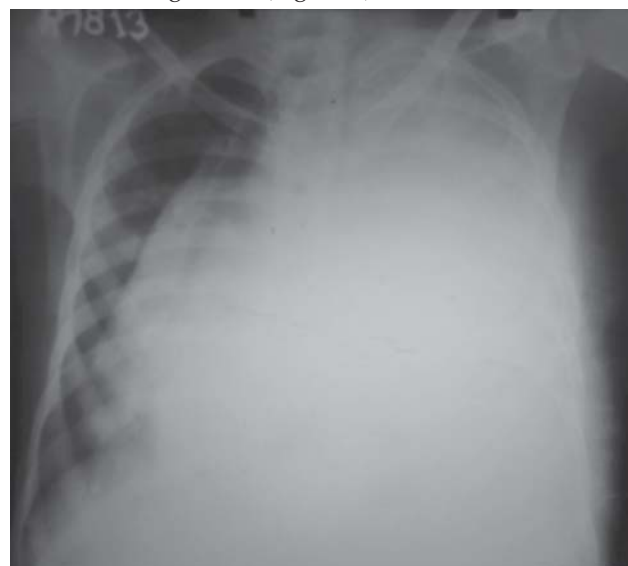

Figure 1. Chest radiograph (postero-anterior view) showing left-sided homogeneous opacity with tracheal and mediastinal shift towards the right.

[Received: November 12, 2014; accepted: January 9, 2015]

**Correspondence and reprint requests:** Dr S.K. Verma, Professor, Department of Pulmonary Medicine, King George's Medical University, Lucknow-226 003 (Uttar Pradesh), India; E-mail: drskverma@rediffmail.com

Ultrasonography of whole abdomen was suggestive of a heterogeneous, predominantly hypoechoic lesion with internal vascularity covering whole of the abdomen extending from epigastrium mainly on the left side to the pelvis pushing the intra-abdominal vessels to the right and bowel loops posteriorly with a mild peritoneal collection of fluid. Computed tomography (CT) of thorax and abdomen revealed the mass as an ill-defined heterogeneously enhancing soft tissue attenuation lesion (Figures 2 and 3).

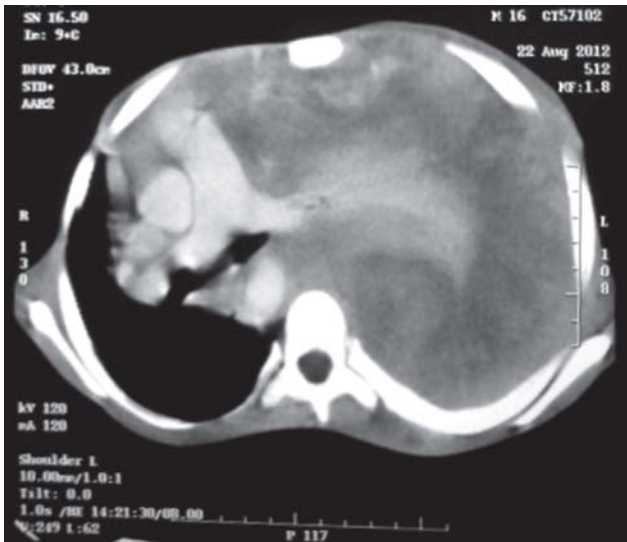


Figure 2. Computed tomography of thorax showing left-sided intra-thoracic mass with mediastinal shift to the right.

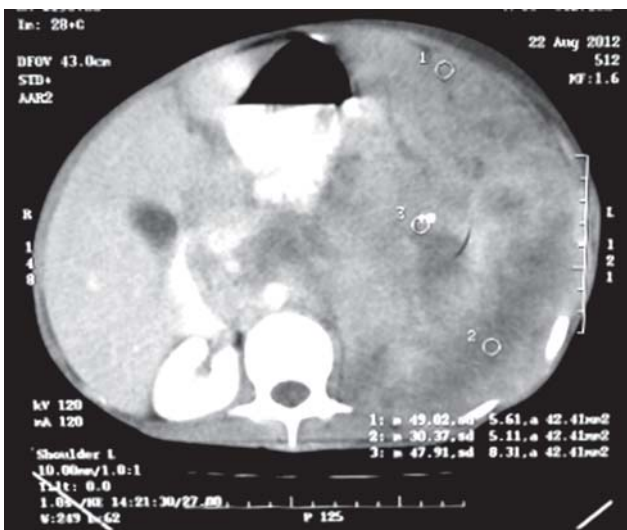


Figure 3. Computed tomography of the abdomen showing left-sided intra-abdominal mass shifting other structures to the right.

A fine needle aspiration from the left axillary lymph node showed a dual population of abnormal cells, majority being large cells with moderate amount of cytoplasm with vacuolation. Nuclear chromatin was coarse and majority of cells showed round nuclear outline. Cytomorphology was suggestive of non-Hodgkin's lymphoma (Burkitt's type) (Figure 4). Bone

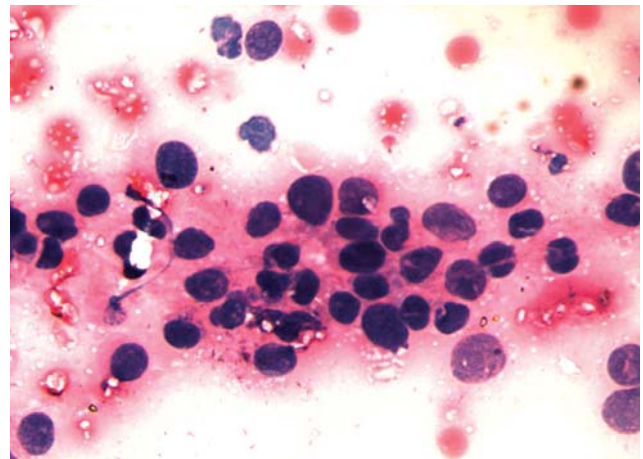


Figure 4. Cytomorphology suggestive of non-Hodgkin's lymphoma (Burkitt's type).

marrow examination revealed early lymphomatous infiltration. However, the patient's attendants refused further work-up and treatment.

## Discussion

Burkitt's lymphoma, one of the highly aggressive B-cell non-Hodgkin's lymphomas, is characterised by translocation and deregulation of the *c-myc* gene on chromosome 8.<sup>1</sup> With a doubling time of less than 24 hours, it is the fastest growing human tumour.<sup>2,3</sup> Burkitt's lymphoma can be divided into three main clinical variants: (i) the endemic, (ii) the sporadic and (iii) the immunodeficiency-associated variants. The endemic variant is commonly occurs in equatorial Africa being the most common malignancy among children in that area. Reduced resistance to Epstein-Barr virus (EBV) has been attributed to coexistence of chronic malaria in these children. The common sites involved include the jaw among other facial bones, distal ileum, cecum, ovaries, kidney or the breast. The sporadic variant is seen outside Africa. The tumour cells show a similar appearance to that of classical or endemic Burkitt's lymphoma. Impaired immunity is believed to favour infection with EBV. The ileocecal region is commonly involved. Jaw involvement is less common when compared to the endemic variant. Immunodeficiency-associated Burkitt's lymphoma is usually associated with HIV infection<sup>4</sup> or occurs in post-transplant patients on immunosuppressive medications.

Burkitt's lymphoma occupies 2% of cancers of the same blood cells.<sup>5</sup> No racial predilection is reported and males are affected 2 to 3 times more often than females. Clinical manifestations of Burkitt's lymphoma depend on the primary and secondary site of involvement. It commonly presents as an abdominal (sporadic type) or head and neck (endemic type) disease with involvement of bone marrow or central nervous system (CNS). Manifestations include painless rapidly growing lymph node swelling, cough, superior vena

cava syndrome, dyspnoea with thoracic extension, abdominal masses, intestinal obstruction, intussusceptions like symptoms and ascites or localised bony pain. Burkitt's lymphoma is reported to present as abdominal or pelvic mass in 45% cases with gastrointestinal tract involvement *per se* in 22.5%.<sup>6</sup> Contiguous involvement of thorax, abdomen and pelvis is rare. Our patient presented with dyspnoea, chest pain, fever and progressive abdominal distension at the same time, probably due to the contiguous involvement of thorax, abdomen and pelvis. A separate staging system for Burkitt's lymphoma has been developed by Ziegler, whereas Levine *et al*, classified the cases of American Burkitt's lymphoma as follows<sup>7</sup>: Stage I — single tumour mass (extra-abdominal 1A or abdominal 2A); Stage II — two separate tumour masses on the same side of the diaphragm; Stage III — involvement of more than two separate masses or disease on both the sides of the diaphragm, and Stage IV — pleural effusion, ascitis or involvement of the CNS (malignant cells in the cerebrospinal fluid) or bone marrow.

Histologically, Burkitt's cells are homogeneous in size and shape, with round to oval nuclei and slightly coarse chromatin, with multiple nucleoli and intensely basophilic vacuolated cytoplasm containing contains neutral fat. Immunohistochemistry by staining with Ki-67, CD-19, CD-20, CD-22, CD-79a protein may be useful in the diagnosis.<sup>8,9</sup> The hallmark of Burkitt's lymphoma is the presence of a 'starry sky' appearance (also observed in other highly proliferative lymphomas), caused by the presence of scattered macrophages phagocytising cell debris and apoptotic cells.

The primary modality of treatment is multi-agent systemic chemotherapy along with intrathecal chemotherapy. Debulking surgery is rarely useful and is used mainly to obtain tissue for biopsy and diagnosis. Radiation therapy is useful in the presence of CNS involvement in Burkitt's lymphoma, acute superior vena cava, and acute paraplegias. Regimens commonly used include COPAD (cyclophosphamide, vincristine, prednisone and doxorubicin) or COMP (cyclophosphamide, vincristine, methotrexate, 6-mercaptopurine and prednisone). Intrathecal

chemotherapy with intrathecal methotrexate, hydrocortisone, or Ara-C is used in moderate to severe disease. Patients who develop progressive or relapsed disease require re-induction chemotherapy and either allogeneic or autologous stem cell transplantation. Current intensive chemotherapy regimens have shown long-term, disease-free survival in about 90% of pediatric and 50% to 60% of adult patients with Burkitt's lymphoma. Massive acute destruction of the tumour cells during initial chemotherapy due to the rapid growth rate may result in tumour lysis syndrome requiring renal dialysis. In the abdominal form of the disease, rapid tumour growth may result in intestinal obstruction; renal failure may occur from tumour infiltration of the kidneys.

## References

1. Kanbar AH. In: DeVita VT, Jr, Hellman S, Rosenberg SA, editors *Cancer: Principles and Practice of Oncology*; Vol 2; 5<sup>th</sup> edition. Philadelphia: Lippincott Williams & Wilkins; 1997:pp 2157–9.
2. Ugar DA, Bozkaya S, Karaca I, Tokman B, Pinarli FG. Childhood craniofacial Burkitt's lymphoma presenting as maxillary swelling: report of a case and review of literature. *J Dent Child (Chic)* 2006;73:45–50.
3. Wood RE. Malignant diseases of the jaws. In: White SC, Pharaoh MJ, editors *Oral Radiology: Principles and Interpretations*. St Louis: Mosby; 2004: pp 450–1.
4. Bellan C, Lazzi S, De Falco G, Nyongo A, Giordano A, Leoncini L. Burkitt's lymphoma: new insights into molecular pathogenesis. *J Clin Pathol* 2003;56:188–92.
5. Turgeon, Mary Louise. *Clinical Hematology: Theory and Procedures*. Hagerstown: Lippincott Williams & Wilkins.2005; pp. 283. "Frequency of lymphoid neoplasms. (Source: Modified from *WHO Blue Book on Tumour of Hematopoietic and Lymphoid Tissues*. 2001:p. 2001.)"
6. Biko DM, Anupindi SA, Hernandez A, Kersun L, Bellah. Childhood Burkitt lymphoma: abdominal and pelvic imaging findings. *AJR Am J Roentgenol* 2009;192:1304–15.
7. Patton LL, McMillan CW, Webster WP. American Burkitt's lymphoma: a 10-year review and case study. *Oral Surg Oral Med Oral Pathol* 1990;69:307–16.
8. Pramanik R, Paral CC, Ghosh A. Pattern of solid malignant tumours in children: a 10 year study. *J Indian Med Assoc* 1997;95;107–8.
9. Ferry JA. Burkitt's lymphoma: clinicopathological feature and differential diagnosis. *Oncologist* 2006;11:375–83.