

Ortner's Syndrome: Unusual Entity of Pulmonary Hypertension in Pulmonary Tuberculosis

Lokesh Maan¹, V.K. Jain¹, Mahesh Kumar¹ and Rajendra Takhar²

Department of Respiratory Medicine, Mahatma Gandhi Medical College and Hospital¹, Jaipur and Government Medical College², Kota (Rajasthan), India

Abstract

Ortner's syndrome is an uncommon condition presenting as hoarseness of voice due to left recurrent laryngeal nerve palsy caused by mechanical affection of the nerve from enlarged cardiovascular structures. Here, we report a case of a 42-year-old male, presented with hoarseness of voice (Ortner's syndrome) due to sequelae of treated pulmonary tuberculosis. [Indian J Chest Dis Allied Sci 2016;58:257-259]

Key words: Ortner's syndrome, Hoarseness, Laryngeal nerve palsy, Pulmonary tuberculosis, Pulmonary arterial hypertension.

Introduction

Ortner's syndrome, first described in 1897 in patients with left atrial enlargement due to mitral valve stenosis.¹ Since then various authors have recorded their experiences of recurrent laryngeal nerve involvement in various cardiac disorders, such as Eisenmenger complex, left ventricular failure, atrial septal defect, patent ductus arteriosus, primary pulmonary hypertension, recurrent pulmonary artery embolism, mitral regurgitation, atrial myxoma, left ventricular aneurysm, cor-pulmonale and various types of aortic aneurysms.²

Case Report

A 42-year-old male presented with chief complaints of hoarseness of voice for last three months which slowly progressed to total loss of voice. It was associated with breathlessness on exertion and generalised weakness. There were no other symptoms, like fever, cough, chest pain, haemoptysis, symptoms suggestive of upper respiratory infection and gastro-oesophageal reflux. He was treated in the past for pulmonary tuberculosis (TB) five years ago. Initially he was started on Category I thrice weekly intermittent treatment, under the Revised National Tuberculosis Control Programme (RNTCP); as the patient had "treatment failure" he was started on Category II thrice-weekly intermittent treatment under RNTCP." Patient denied history of any other systemic illness. Initially within few weeks of change in voice, he consulted a local practitioner and was prescribed some medication, but did not get any relief. The hoarseness had progressed and there was a total

loss of voice. He, therefore, reported to our out-patient service of Department of Respiratory Medicine.

After initial assessment, patient was referred to otorhinolaryngology department for fiberoptic laryngoscopy, which revealed left vocal cord (VC) palsy with immobile cord in paramedian position. The rest of the larynx and nasopharynx were normal. General and systemic examinations were unremarkable. Haematological, serological investigations (HIV I and II and HBSAg) and serum biochemistry were normal. Sputum samples were negative twice for acid-fast bacilli. Chest radiograph showed bilateral upper zone fibrosis with prominent and pulled up both hila with cardiomegaly and low placed diaphragm (Figure 1).

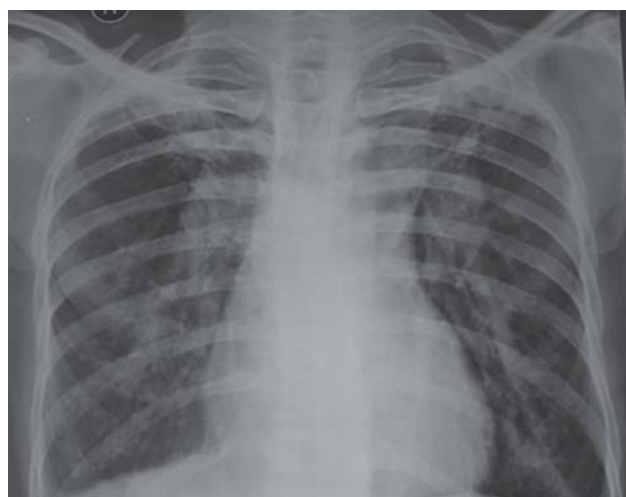


Figure 1. Chest radiograph (postero-anterior view) showing bilateral upper zone diffuse fibrosis with both hila prominent and shifted upwards.

[Received: November 17, 2015; accepted after revision: March 4, 2016]

Correspondence and reprint requests: Dr Lokesh Maan, Assistant Professor, Department of Respiratory Medicine, Mahatma Gandhi Medical College and Hospital, Sitapura, Tonk Road, Jaipur-302 022 (Rajasthan), India; E-mail: drlokeshmaan@gmail.com

Spirometry revealed a forced expiratory volume in the first second (FEV_1) to forced vital capacity (FVC) ratio of 60%, a $FEV_1=0.71L$ (19% of predicted) suggestive of severe obstruction without significant reversibility. Contrast-enhanced computed tomography with high resolution sections was suggestive of post-pulmonary TB sequelae with bilateral upper lobes fibrosis, bronchiectasis, centriacinar and paraseptal emphysema. There was no evidence of mediastinal fibrosis or adenopathy. Main pulmonary trunk (37mm) along with both left (30mm) and right (34mm) pulmonary arteries were significantly dilated, causing compression and posterior displacement of trachea and both mainstem bronchi (Figures 2 & 3). Fibreoptic bronchoscopy showed left vocal cord palsy and distorted carina. No intra-luminal growth was observed. Trans-thoracic two-dimensional echocardiography showed

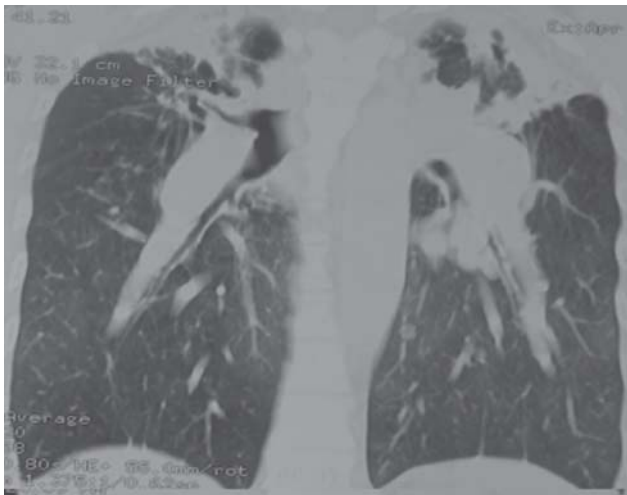


Figure 2. Contrast-enhanced computed tomography of thorax (sagittal section) showing bilateral upper zone pleuroparenchymal fibrosis along with pulled up hila and dilated pulmonary arteries.

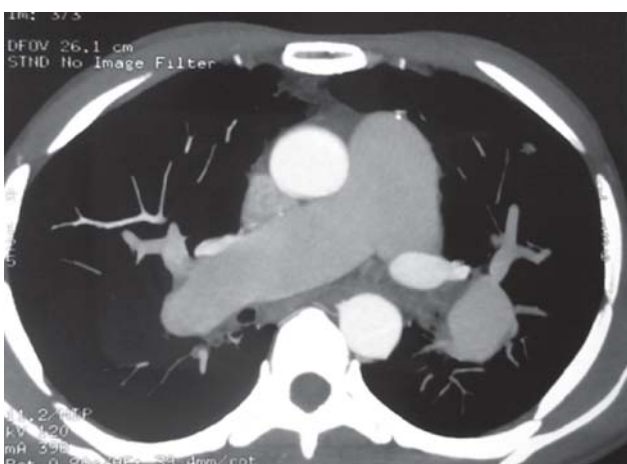

Figure 3. Contrast-enhanced computed tomography of thorax (axial view) showing grossly dilated pulmonary trunk and arteries as comparison to other mediastinal structures which suggestive of pulmonary hypertension.

dilated right atrium and right ventricle, mild tricuspid regurgitation, mean pulmonary arterial systolic pressure of 52mmHg and an ejection fraction of 60%, suggestive of pulmonary hypertension, cor-pulmonale. Further evaluation of pulmonary hypertension by right heart catheterisation was planned but was refused by the patient. A diagnosis of Ortner's syndrome due to entrapment of recurrent laryngeal nerve between enlarged pulmonary arteries and distorted bronchovascular structures was made.

The patient was managed with inhaled bronchodilators and oral methylxanthines sildenafil citrate 20mg thrice daily. On subsequent follow-up, breathlessness and loss of voice improved significantly but hoarseness still persisted.

Discussion

Ortner's syndrome was first described by Nobert Ortner, an Austrian physician in 1897, in a patient with mitral stenosis with dilated left atrium.¹ Ortner explained that hoarseness was caused by compression of the left recurrent laryngeal nerve by enlarged left atrium. Though an initially enlarged left atrium was thought to be the main culprit, the current understanding favours pressure in the pulmonary artery playing the most important role in causing the nerve compression in a majority of the cases.³

The left recurrent laryngeal nerve, a branch of the vagus, hooks around the ligamentum arteriosum as it crosses the arch of aorta and then ascends in the groove between trachea and oesophagus to enter the larynx behind the cricothyroid joint.⁴ Lesions affecting the left vagus nerve or its laryngeal branch causing left vocal cord palsy and subsequently hoarseness of voice (Ortner's syndrome). However, it is a recognised complication of a number of conditions including atrial septal defects, patent ductus arteriosus, pulmonary hypertension, aortic aneurysm, mediastinal mass or adenopathy and post surgical injury. The palsy results from the recurrent laryngeal nerve being compressed between the pulmonary artery and the aorta or aortic ligament as a result of enlargement of one or more of these structures due to cardiopulmonary pathology.⁵ Unilateral damage to the recurrent laryngeal nerve usually causes hoarseness, as observed in our patient. The most common manifestation of Ortner's syndrome is hoarseness of voice. Unilateral vocal cord paralysis increases the risk of aspiration which may be present in up to 40% of patients.⁶ Therefore, early evaluation and management of underlying cause of Ortner's syndrome is required.

Many conditions like open negative syndrome, bronchiectasis, obstructive airway disease,

respiratory insufficiency, emphysema, amyloidosis, disseminated calcification of lung, pulmonary hypertention and cor-pulmonale have been described in the literature as sequelae of pulmonary TB. Important causes of hoarseness of voice in tuberculous involvement of the larynx include inflammation of the vocal cord of ventricular fold or crico-arytenoid joint. Vocal cord palsy consequent upon fibrosis of the lung presented as a late complication of healed pulmonary TB.⁷ Fibrosis in chronic pulmonary TB in upper lobes and scar tissue may affect the recurrent laryngeal nerve. It may be related to enlarged tuberculous nodules or compression on the recurrent laryngeal nerve in scar tissue or fibrosis. Recurrent laryngeal nerve may be damaged due to compression by enlarged tuberculous lymph nodes and anatomical swellings at arteriopulmoner window and aortic arch. Partial recovery of the recurrent laryngeal nerve functions and dysphonia after treatment showed that both mechanical compression and mediastinal fibrosis are effective.⁸

Infrequency of clinical reports referring to the cause of unilateral vocal cord palsy secondary to pulmonary hypertension in combination with distorted bronchovascular structure in treated pulmonary TB, prompted us to present this case for publication.

The mechanism of pulmonary hypertension in treated pulmonary TB patients is thought to result from residual pulmonary structural damage and pulmonary function abnormalities leading to gas exchange abnormalities and chronic hypoxia. Repeated secondary respiratory tract infections, caused by residual chest radiographic abnormalities, play an important role in the pathogenesis of pulmonary hypertension in treated pulmonary TB patients.⁹ A case of Ortner's syndrome due to pulmonary hypertension secondary to concomitant mitral stenosis and bronchiectasis has been reported.¹⁰ Bilateral bronchiectasis probably contributed to the major share of the severity of pulmonary hypertension, which ultimately caused dilatation of the pulmonary arteries.¹⁰

In our case, bilateral upper zone pleuro-parenchymal fibrosis along with distortion of

bronchovascular structures occurred with time as sequelae of pulmonary TB. Pulmonary structural damage and pulmonary function abnormalities (severe obstruction) leading to gas exchange abnormalities and chronic hypoxia which have been shown to be a risk factor for pulmonary hypertention. Left recurrent laryngeal nerve was most likely compressed in mediastinum between dilated pulmonary artery and distorted bronchovascular structures. Presence of dual pathology in our case, pulmonary artery hypertention with distorted bronchovascular structures, aggravate the hoarseness of voice and ultimately leads to dysphonia. With proper management of obstructive airways disease and pulmonary hypertension, the patient's symptoms significantly improved over a time. Some hoarseness persisted possibly due to irreversible distorted bronchovascular structural changes in treated pulmonary TB. Presence of dual pathology may make management difficult and worsen the prognosis.

References

1. Ortner NI. *Recurrensla'hmung bei Mitralstenose*. *Wien Klin Wochenschr* 1897;10:753-5.
2. Subramaniam V, Herle ATV, Mohammed N, Thahir M. Ortner's syndrome: case series and literature review. *Braz J Otorhinolaryngol* 2011;77:559-62.
3. Lee SI, Pyun SB, Jang DH. Dysphagia and hoarseness associated with painless aortic dissection: a rare case of cardiovocal syndrome. *Dysphagia* 2006;21:129-32.
4. Last RJ. *Last's Anatomy, Regional and Applied*, 9th edition. Edinburgh: Churchill Livingstone;1994:261.
5. Panwar SS, Mehta AK, Verma RK, Mukherji B. High altitude induced Ortner's syndrome. *Med J Armed Forces India* 2004;60:182-3.
6. Meyer E, Jonas NE, Zühlke LJ. Ortner syndrome. *S Afr J Child Health* 2008;2:170-1.
7. Raj B, Krishna Bihari, Kumar P, Chawla RK, Janmeja AK, Chopra RK. Unilateral vocal cord paralysis-unusual sequelae of healed pulmonary tuberculosis. *Indian J Tuberc* 1987;34:150-2.
8. Dikici O, Bayar Muluk N. Left vocal cord paralysis due to lymphadenopathy of mediastinal tuberculosis. *J Med Updates* 2013;3:98-100.
9. Kapoor SC. Pathogenesis of cor pulmonale in pulmonary tuberculosis. *Indian J Tuberc* 1986;33:167-70.
10. Monwarul Islam AKM, Zaman S, Doza F. Ortner's syndrome due to concomitant mitral stenosis and bronchiectasis. *Korean Circ J* 2012;42:507-10.

NATIONAL COLLEGE OF CHEST PHYSICIANS (INDIA)

Fellowship/Membership Fee

Membership (Annual)	:	₹ 500.00
Membership (Life)	:	₹ 5000.00
Fellowship	:	₹ 5000.00
Enrolement (new members only)	:	₹ 1000.00

Payments should be made by Demand Draft, drawn in favour of the National College of Chest Physicians (I). Outstation cheques will not be accepted.

Annual membership is valid for one financial year (April-March) only.

Forms & others details are available on the website: www.nccpindia.com

*Sd/-
Secretary*

NATIONAL COLLEGE OF CHEST PHYSICIANS (INDIA)

Fellows and Members of the College are requested to mention their old address also while informing for change of address alongwith their Fellowship/ Membership number to the Secretary, NCCP (I) and/or to Publication Department, IJCDAS to avoid any mistake/delay in mailing the Journal's copy as well as College's information.

*Sd/-
Secretary*