

## Systemic Sclerosis Sine Scleroderma: A Rare Entity

Aashish Kumar Singh and Nalin Joshi

Institute of Respiratory Diseases, S.M.S. Medical College, Jaipur (Rajasthan), India

### Abstract

Systemic sclerosis sine scleroderma is a rare form of limited systemic sclerosis, but without skin involvement. It does not differ in its clinical or laboratory features and prognosis from classical systemic sclerosis. In the absence of cutaneous signs/symptoms, its diagnosis is delayed leading to significant morbidity and mortality. We report the case of a 28-year-old male who presented with dyspnoea on exertion and Raynaud's phenomenon. Diagnostic evaluation confirmed systemic sclerosis sine scleroderma and pulmonary artery hypertension.

[Indian J Chest Dis Allied Sci 2016;58:265-267]

**Key words:** Systemic Sclerosis, Raynaud's phenomenon, Lung.

### Introduction

Systemic sclerosis is a connective tissue disorder of unknown aetiology. Skin thickening is considered as a hallmark of it, which distinguishes it from other connective tissue disorders. On the basis of pattern of skin involvement, it is broadly classified into diffuse and limited variety. Diffuse systemic sclerosis involves skin of extremities, face and trunk while limited systemic sclerosis involves only distal extremities and face with no involvement of trunk. A small subset (10%) of patients with limited systemic sclerosis has all other features of the disease without any skin involvement and is known as systemic sclerosis sine scleroderma.

### Case Report

A 28-year-old male came to our out-patient department with complaints of progressive dyspnoea on exertion since last six months and cough with minimal expectoration since five months. He also gave a four-year history of bluish discolouration of fingers during winters and on exposure to cold water (Figure 1).

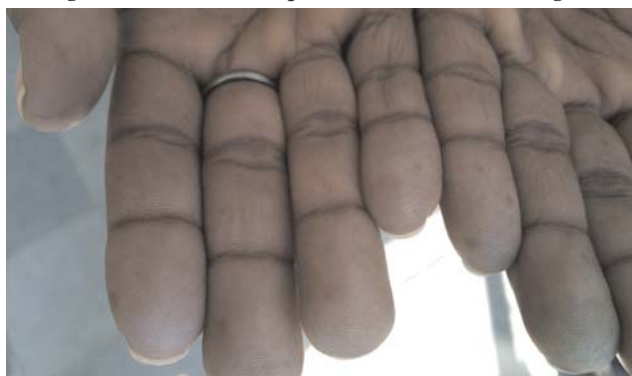

Figure 1. Photograph showing Raynaud's phenomenon on exposure to cold water (arrows).

There was no other significant past medical history. He was a non-smoker and non-alcoholic and a shopkeeper by profession.

On examination, his pulse was 110/min, blood pressure 110/70 mmHg, respirations 24/min; he was afebrile. Respiratory system examination revealed inspiratory crepitations over bilateral infra-scapular areas. Cardiac auscultation was within normal limits. Pitted scars were present on fingers. Skin tightening was not evident. Rest of the systemic examination was normal. Chest radiograph revealed reticulonodular opacities on both the lung fields (Figure 2). Laboratory investigations were within normal limits. Sputum smear was negative for acid-fast bacilli.

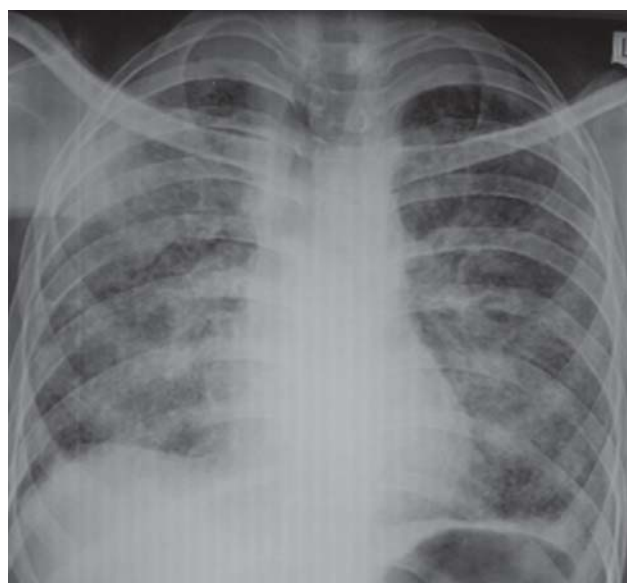


Figure 2. Chest radiograph (postero-anterior view) showing bilateral nodular opacities.

[Received: August 11, 2015; accepted after revision: February 9, 2016]

**Correspondence and reprint requests:** Dr Aashish Kumar Singh, A13 B Ram Marg, Vijay Path, Tilak Nagar, Jaipur-302 004 (Rajasthan), India; E-mail: Singhaashish@yahoo.com

Serological testing for human immunodeficiency virus (HIV) was non-reactive. Contrast enhanced computed tomography of chest revealed bilateral pleural thickening, septal thickening and ground-glass opacity in lower lobes (Figure 3). Electrocardiogram was within normal limits. Two-dimensional echocardiography revealed mild tricuspid regurgitation, pulmonary artery hypertension (pulmonary artery systolic pressure: 54mmHg) with normal systolic functions. Antinuclear antibody (ANA) was positive by indirect immunofluorescence (IIF) method. He was also tested positive for anti-topoisomerase (Scl-70) antibody.

He was diagnosed to have systemic sclerosis sine scleroderma. He was prescribed oral diuretics for pedal oedema (torsemide 10mg twice a day), endothelin receptor antagonist (ambrisentan 5mg per day) to prevent right heart failure, pentoxifylline 400mg thrice daily and intravenous cyclophosphamide, inhaled bronchodilators and is doing well on follow-up.

based on presence and extent of skin involvement. Limited systemic sclerosis involves skin distal to elbow and knees only, whereas diffuse variety involves proximal extremities and or trunk in addition to distal thickening. Most of these patients have positive antinuclear antibody by indirect immunofluorescence (85% to 90%). Among scleroderma specific antibodies, anti-topoisomerase (Scl-70) and anti-ribonucleic acid (RNA) polymerase III are more specific for diffuse variety whereas anti-centromere antibody is more specific for limited variety. Presence of anti Scl-70 antibody is a strong predictor of development of complications like pulmonary fibrosis and digital ulcers, whereas the absence of anti-centromere antibody strongly predicts the presence of synovitis, joint contractures and pulmonary fibrosis.

Systemic sclerosis sine scleroderma is a variant of limited systemic sclerosis which has all other features of this disease except skin involvement. In a study,<sup>3</sup> Scl-70 antibodies were present in 58 (60.4%) of 96 patients with diffuse systemic sclerosis. In contrast,

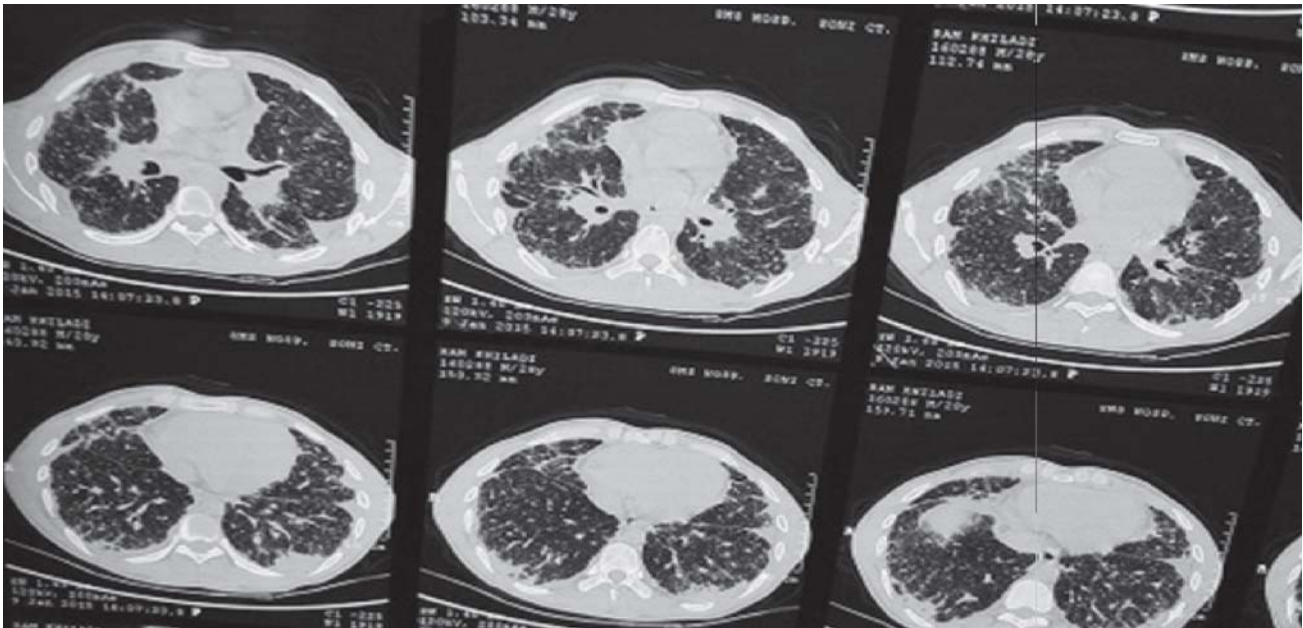


Figure 3. Contrast enhanced computed tomography of chest showing bilateral pleural thickening, septal thickening and ground-glass opacity in lower lobes.

## Discussion

Systemic sclerosis is a chronic connective tissue disease affecting skin and internal organs by widespread micro-vascular damage and excessive deposition of collagen.<sup>1</sup> American College of Rheumatology has given preliminary classification criteria in 1980<sup>2</sup>; the major criteria include: skin thickening proximal to metacarpal pharyngeal joints and minor criteria include sclerodactyly, digital pitting scars and bibasilar pulmonary fibrosis. It is further classified into limited and diffuse variety

only 7 out of 113 patients with limited systemic sclerosis and only 1 out of four patients with sine scleroderma were positive for anti Scl-70 antibodies. Among patients with systemic sclerosis, anti Scl-70-positive patients were characterised by fibrotic signs.

The first case of this entity was reported by Abraham *et al*<sup>4</sup> in 1954 and the term systemic sclerosis sine scleroderma was coined by Rodnan and Fennel in 1962.<sup>5</sup> Poormoghim *et al*<sup>6</sup> described diagnostic criteria for it, which were fulfilled in our case. Till 2012, excluding individual case reports, a total of 139

cases of this condition have been documented in the literature.<sup>7</sup> Analysis of 108 published cases found peripheral vascular system involvement in all, gastrointestinal manifestations in 82% and pulmonary involvement in 66% of cases.<sup>8</sup> In a study from Brazil,<sup>9</sup> of the 947 patients with systemic sclerosis, 79 (8.3%) had systemic sclerosis sine scleroderma. Oesophageal involvement was most frequent (83.1%), followed by interstitial lung disease (56.9%) and pulmonary hypertension (22.8%).

To the best of our knowledge, there is a single case series published that from India by Sharma *et al*<sup>10</sup> who reported *calcinosis cutis* as a presenting feature. Pauling *et al*<sup>11</sup> reported that pulmonary artery hypertension has also been documented as a presenting feature. Present case report also documents pulmonary artery hypertension as a presenting feature along with interstitial lung disease and presence of anti-Scl 70 antibody.

In conclusion, although skin thickening is considered as a hallmark of systemic sclerosis, there should be a high index of clinical suspicion in patients presenting with possible manifestations of systemic sclerosis without sclerodermatous cutaneous involvement because early diagnosis and treatment can reduce the morbidity and mortality.

## References

- Hinchcliff M, Varga J. Systemic sclerosis/scleroderma: a treatable multisystem disease. *Am Fam Physician* 2008;78:961–8.
- Masi AT, Medsger TA, Jr, Rodnan GP, Fries JF, Altman RD, Brown BW, *et al*. Preliminary criteria for the classification of systemic sclerosis (scleroderma). *Arthritis Rheum* 1980;23:581–90.
- Hanke K, Dähnrich C, Brückner CS, Huscher D, Becker M, Jansen A, *et al*. Diagnostic value of anti-topoisomerase I antibodies in a large monocentric cohort. *Arth Res Thera* 2009, 11:R28 (doi:10.1186/ar2622). Available at URL: <http://arthritis-research.com/content/11/1/R28>
- Abrams HL, Carnes WH, Eaton J. Alimentary tract in disseminated scleroderma with emphasis on small bowel. *Arch Intern Med* 1954;94:61–81.
- Rodnan GP, Fennel RH. Progressive systemic sclerosis sine scleroderma. *JAMA* 1962;180:665–70.
- Poormoghim H, Lucas M, Fertig N, Medsger TA. Systemic sclerosis sine scleroderma. *Arthritis Rheum* 2000;43:444–51.
- Simeón-Aznar CP, Fonollosa-Plá V, Tolosa-Vilella C. Registry of the Spanish Network for Systemic Sclerosis: clinical pattern according to cutaneous subsets and immunological status. *Semin Arthritis Rheum* 2012;41:789–800.
- Toya SP, Tzelepis GE. The many faces of scleroderma sine scleroderma: a literature review focusing on cardio-pulmonary complications. *Rheumatol Int* 2009;29:861–8.
- Marangoni RG, Rocha LF, Del Rio APT, Yoshinari NH, Marques-Neto JF, Sampaio-Barros PD. Systemic sclerosis sine scleroderma: distinct features in a large Brazilian cohort. *Rheumatology* 2013;52:1520–4.
- Sharma NL, Mahajan VK, Ranjan N, Sharma VC, Gupta M. Systemic sclerosis sine scleroderma and calcinosis cutis: report of a rare case. *Clin Rheumatol* 2010;29:215–9.
- Pauling JD, Gunawardena H, Coghlan JG, Easaw J, Suntharalingam J, McHugh NJ. Pulmonary artery hypertension as the presenting feature of systemic sclerosis sine scleroderma. *Rheumatol Oxf Engl* 2008;47:1431–2.

### **RADIOLOGY FORUM**

It is proposed to extend the scope of the Radiology Forum of our Journal by inviting our readers as well as other workers in the field of Respiratory Medicine to submit brief report of patients with interesting clinical and radiological features for publication. These will be published, provided that:

1. The condition is of sufficient clinical and radiological interest;
2. Photographs (10cm×8cm) are of excellent quality for printing (Maximum: 4 photographs);
3. The diagnosis in each case has been confirmed; and
4. The chest radiograph is accompanied by brief clinical account, not exceeding two page typescript (with sub-head: Clinical Summary, Investigations, Diagnosis, Discussion and References)

All the material received for publication under the Radiology Forum section will be evaluated to judge the suitability for publication by our peer-review experts panel.

*Editor-in-Chief*