

CASE REPORT

Superior Vena Cava Syndrome in Pulmonary Adenocarcinoma: A Rare Clinical Presentation and a Different Course of Management

Sanchit Mohan¹, Rohit Kumar², Nitesh Gupta³, Pranav Ish⁴

Received on: 03 April 2024; Accepted on: 03 June 2024; Published on: 10 July 2024



This article is available on www.vpci.org.in

ABSTRACT

Superior vena cava syndrome (SVCS) can be associated with benign as well as malignant causes, NSCLC being the most common malignant cause and is rarely associated with adenocarcinoma of the lung. Symptoms may range from dyspnea to respiratory failure requiring urgent intervention. Endovascular stenting, radiotherapy, and treatment of underlying cancer are required to relieve symptoms. Balloon dilatation of SVC is usually done for SVC secondary to benign disease. We report a case of adenocarcinoma of the lung presenting with SVCS, which responded well to SVC dilatation and chemotherapy.

Keywords: Adenocarcinoma of the lung, Balloon dilatation, Case report, Superior vena cava syndrome.

The Indian Journal of Chest Diseases and Allied Sciences (2024); 10.5005/jp-journals-11007-0115

ABBREVIATIONS USED IN THIS ARTICLE

CT = Computed tomography; NSCLC = Non-small-cell lung cancer; PET = Positron emission tomography; SCC = Squamous cell carcinoma; SCLC = Small-cell lung cancer; SVCS = Superior vena cava syndrome.

INTRODUCTION

Superior vena cava syndrome (SVCS) occurs due to intrathoracic malignancy in the majority of cases. Squamous cell carcinoma (SVC) obstruction is a presenting feature of about 60% of undiagnosed tumors.¹ Non-small-cell lung cancer (NSCLC) accounts for 50% of cases, followed by small-cell lung cancer (SCLC) in 25% and non-Hodgkin lymphoma in 10% of the cases.¹ Squamous cell carcinoma of the lung (SCC), owing to its central location presents more commonly with SVC syndrome than adenocarcinoma.

Superior vena cava causes reduce blood flow to the right atrium from the upper extremities, head, and neck leading to cyanosis, plethora, and edema of upper extremities head, and neck, it can lead to airway narrowing in the larynx and pharynx leading to dyspnea and stridor, cerebral edema causing headache confusion and sometimes coma.²

Possible interventions for SVCS depend upon the grading of SVCS.³ Initial management includes decreasing hydrostatic pressure by elevating the head end. Steroids are used in SVCS to reduce airway or cerebral edema however data is still lacking regarding its efficacy.⁴ Superior vena cava syndrome secondary to malignancy requires management of malignancy however, in life-threatening situations stabilization of airway, breathing, and circulation followed by endovascular recanalization with or without stenting for quick relief of symptoms.⁵

Here we present a case of adenocarcinoma lung presented with SVCS.

¹⁻⁴Department of Pulmonary, Critical Care and Sleep Medicine, Vardhman Mahavir Medical College & Safdarjung Hospital, New Delhi, India

Corresponding Author: Nitesh Gupta, Department of Pulmonary, Critical Care and Sleep Medicine, Vardhman Mahavir Medical College & Safdarjung Hospital, New Delhi, India, Phone: +91 9873096364, e-mail: niteshgupta2107@gmail.com

How to cite this article: Mohan S, Kumar R, Gupta N, *et al.* Superior Vena Cava Syndrome in Pulmonary Adenocarcinoma: A Rare Clinical Presentation and a Different Course of Management. *Indian J Chest Dis Allied Sci* 2024;66(2):74–76.

Source of support: Nil

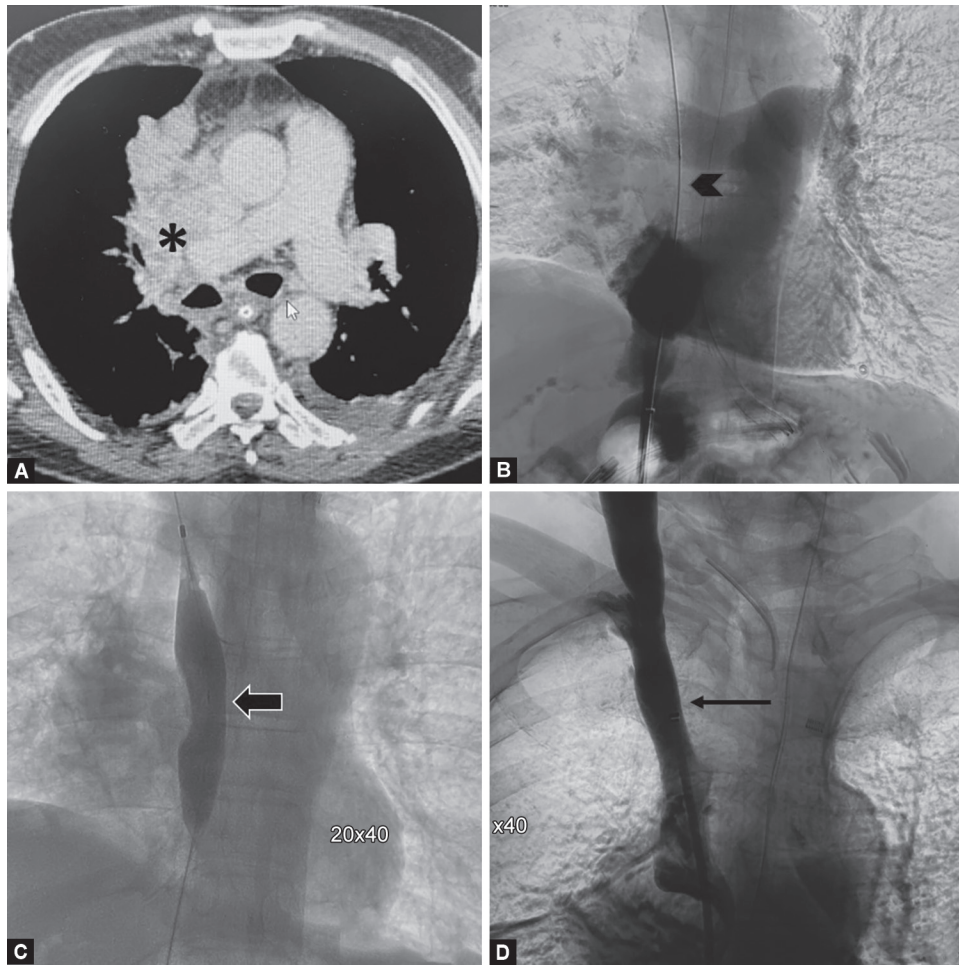
Conflict of interest: None

Patient consent statement: The author(s) have obtained written informed consent from the patient for publication of the case report details and related images.

CASE DESCRIPTION

A 60-year-old male, an active smoker, with a smoking index of 60 pack years presented to the emergency department complaining of shortness of breath for 1 month, which worsened over the last week. It was associated with facial plethora, dizziness, and hoarseness of voice. On examination, he was afebrile, with a heart rate of 135 beats/min, respiratory rate of 32 breaths/min, and SpO₂ of 85% on ambient air. He had stridor, facial puffiness, bilateral upper limb edema, and dilated veins on his chest. The other system examinations were essentially normal. The patient being in respiratory distress was intubated and mechanically ventilated.

Complete blood counts, liver function tests, electrolytes, and glycosylated hemoglobin were within normal limits. Renal functions revealed normal urea and creatinine. Serological status for HIV, hepatitis B, and hepatitis C were negative. On computed tomography

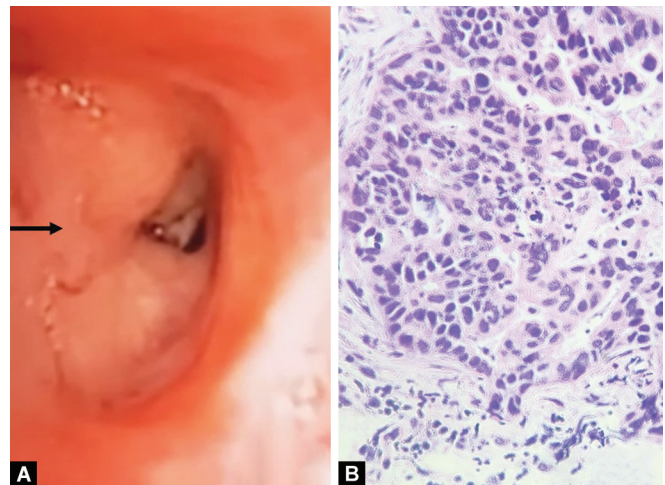


Figs 1A to D: (A) Shows a tumor obstructing the SVC (asterisk); (B) Complete obstruction of flow in SVC (black arrowhead); (C) Balloon dilatation of SVC (thick arrow); (D) Superior vena cava post balloon dilatation with patency (thin arrow)

(CT) of the thorax, he had a mediastinal mass with compression of the superior vena cava extending into the right middle lobe bronchus (Fig. 1A) with bilateral pleural effusion. Fluoroscopic images showed stenosis at the junction of the right IJV and SCV, SVC, and right atrium. There was no flow of dye in SVC when it was injected during venography (Fig. 1B). There was no evidence of thrombosis on CT and fluoroscopic images. Balloon dilatation of the short segment using a 12–40 mm balloon and long segment using a 20–40 mm balloon was done (Fig. 1C) following which obstruction was relieved (Fig. 1D) leading to improvement in facial and ocular edema. Pleural fluid cytology was positive for malignant cells.

Flexible video bronchoscopy demonstrated obstruction of the right middle lobe bronchus (Fig. 2A). Biopsy from the right middle lobe was suggestive of adenocarcinoma. Immunohistochemistry was positive for TTF-1 and negative for p40 (Fig. 2B).

Positron emission tomography-computed tomography (PET-CT) scan did not reveal any other metabolically active site. The next-generation sequencing returned negative for EGFR, ALK, ROS-1, and BRAF mutations. The final diagnosis was stage IVA adenocarcinoma of the lung (cT4N2M1a) with SVC syndrome.



Figs 2A and B: (A) Obstruction of the right middle lobe with endobronchial growth (black thin arrow); (B) Hematoxylin and Eosin stain in 400x showing tumor cells (adenocarcinoma)

The patient was initiated on chemotherapy (pemetrexed plus carboplatin), however patient developed neutropenia and subsequent infection and later succumbed to illness.

DISCUSSION

Superior vena cava syndrome most commonly occurs as a result of mediastinal malignancies such as lung cancer, non-Hodgkin's lymphoma, and metastatic tumors. Amongst lung cancer, 10% of patients are diagnosed as SCLC. Only 2–4% of other lung malignancies can result in SVCS.⁶ Index patient, who presented with SVC syndrome, was a chronic smoker and diagnosed with adenocarcinoma lung and was negative for EGFR/ALK/ROS-1/BRAF.

Superior vena cava syndrome may result due to extrinsic compression by the tumor mass itself, or due to mediastinal lymphadenopathy, as well as by invasion into the vasculature. However, the current patient had a nodal mass that was invading the right middle lobemucosa. The normal cervical venous pressure ranges from 2 to 8 mm Hg but due to narrowing of SVC the pressure may rise to 20–40 mm Hg leading to elevated hydrostatic pressure causing edema of the head, neck, upper torso, eyelid, larynx, and pharynx which may lead to symptoms like hoarseness, stridor, cough, dyspnea, dysphagia.⁷ Stenosis of more than 60% of SVC results in the formation of collaterals. Vascular involvement is dictated by the site of obstruction (pre-azygos, azygos, post-azygos). The right superior intercostal system is an efficient collateral system. Azygos circulation may render the patients with pre-azygos obstruction of SVC to remain asymptomatic for variable periods.⁸

Treatment of SVC syndrome with threatened airway and grade 4 symptoms requires urgent veno-gram and endovascular treatment. A study by Tzifa A et al. included 63 patients with benign causes of SVCS secondary to post-cardiac surgery and non-cardiac surgery, 27 underwent balloon dilatation alone and 36 underwent stenting, out of which obstruction was relieved in 21 patients (78%) underwent balloon dilatation and 36 patients (100%) underwent stenting.⁹

Endovascular balloon dilatation has been tried in benign causes of SVCS however data for malignant causes is scarce. The index patient underwent a venogram followed by balloon dilatation and there was the excellent resolution of symptoms post-SVC dilatation.

CONCLUSION

Adenocarcinoma is a rare malignancy associated with SVC syndrome. Treatment usually requires SVC stenting. However,

balloon dilatation is also an option with good results in patients in whom stenting is not feasible.

ORCID

Sanchit Mohan  <https://orcid.org/0000-0002-3364-1037>

Rohit Kumar  <https://orcid.org/0000-0001-6398-7840>

Nitesh Gupta  <https://orcid.org/0000-0002-5842-5584>

Pranav Ish  <https://orcid.org/0000-0003-1701-4970>

REFERENCES

1. Wilson LD, Detterbeck FC, Yahalom J. Superior vena cava syndrome with malignant causes. *N Engl J Med* 2007;356(18):1862–1869. DOI: 10.1056/NEJMcp067190.
2. Kvale PA, Selecky PA, Prakash UB, et al. Palliative care in lung cancer: ACCP evidence-based clinical practice guidelines (2nd edition). *Chest* 2007;132(3 Suppl):368S–403S. DOI: 10.1378/chest.07-1391.
3. Yu JB, Wilson LD, Detterbeck FC. "Superior vena cava syndrome—A proposed classification system and algorithm for management". *J Thorac Oncol* 2008;3(8):811–814. DOI: 10.1097/JTO.0b013e3181804791.
4. Cheng S. "Superior vena cava syndrome: A contemporary review of a historic disease". *Cardiol Rev* 2009;17(1):16–23. DOI: 10.1097/CRD.0b013e318188033c.
5. Lanciego C, Pangua C, Chacon JI, et al. "Endovascular stenting as the first step in the overall management of malignant superior vena cava syndrome". *AJR Am J Roentgenol* 2009;193(2):549–558. DOI: 10.2214/AJR.08.1904.
6. Straka C, Ying J, Kong FM, et al. Review of evolving etiologies, implication and treatment strategies for the superior vena cava syndrome. *Springerplus* 2016;5:229. DOI: 10.1186/s40064-016-1900-7.
7. Mineo TC, Ambrogi V, Nofroni I, et al. Mediastinoscopy in superior vena cava obstruction: Analysis of 80 consecutive patients. *Ann Thorac Surg* 1999;68(1):223–226. DOI: 10.1016/s0003-4975(99)00455-5.
8. Lepper PM, Ott SR, Hoppe H, et al. Superior vena cava syndrome in thoracic malignancies. *Respir Care* 2011;56(5):653–666. DOI: 10.4187/respcare.00947.
9. Tzifa A, Marshall AC, McElhinney DB, et al. Endovascular treatment for superior vena cava occlusion or obstruction in a pediatric and young adult population: A 22-year experience. *J Am Coll Cardiol* 2007;49(9):1003–1009. DOI: 10.1016/j.jacc.2006.10.060.